About the Authors

Thomas J Vogl

In 1982, Thomas J Vogl graduated from Ludwig Maximilian University of Munich (Germany) with an MD. In 1988, he obtained the position of Assistant Professor at the University of Munich, in 1992 Associate and Full Professor of the Free University of Berlin (Germany) and in 1995 Professor of the Humboldt University of Berlin (Germany). Currently, he is Head of the Department of Diagnostic and Interventional Radiology at the University of Frankfurt (Germany). He has been the recipient of several honorary awards, and is a member of multiple national and international radiological and oncological societies, as well as of editorial boards of journals. He has specialized in interventional oncology, vascular procedures, multidetector computed tomography, MRI, evaluation of contrast agent and magnetic resonance-guided procedures.

Khashayar Vatankhah

Khashayar Vatankhah graduated from Iran Medical University, (Tehran) in 1993. He has worked as a scientific researcher in the Department of Diagnostic and Interventional Radiology at the University Hospital Frankfurt since 2009. Furthermore, he is a member of many national and international medical societies related to radiology.

Jijo Paul

Jijo Paul graduated from the University of Frankfurt with a PhD in medical physics in 2011. He has worked as a scientific researcher in the Department of Diagnostic and Interventional Radiology at the University Hospital Frankfurt since 2009. He earned his MSc in medical radiation physics from Manipal University (India) in 2007, and an MPhil in physics from Vinayaka Missions University (Salem, India) in 2009. He has published many research articles with various high-ranking journals; furthermore, he is a member of multiple medical physics, oncology and radiological international societies.

Chapter 5

Laser-induced thermotherapy for the treatment of pulmonary tumors

Thomas J Vogl, Khashayar Vatankhah & Jijo Paul

The aim of this chapter is to evaluate treatment techniques and their results using laser-induced thermotherapy (LITT) on lung metastatic lesions. This chapter explains the complete clinical strategy regarding percutaneous ablation of metastatic lung tumors using LITT. Furthermore, we discuss theoretical background, basic principles, tools/techniques, technical problems and current protocols used for the treatment. LITT is a safe, noninvasive technique to improve outcome, with better local tumor control, increased survival rate and relief of clinical symptoms.

doi:10.2217/FMEB2013.13.147

Due to the comparably high penetrability of photons and the possibility of complication-free transfer of energy through guide light, a neodymium-doped yttrium aluminum garnet laser (1064 nm) is mostly used for laser-induced thermotherapy (LITT). The energy is applied to the target tissue using special laser applicators. The energy of laser light is absorbed, which causes coagulation of tumor as well as surrounding normal tissue.

Lung tumors are the most important group of cancers and are the leading cause of cancer-related patient deaths worldwide (0.9 million population) [1]. Pulmonary tumors can be classified as primary or metastatic; however, small-cell lung carcinoma and non-small-cell lung carcinoma are classifications for primary lung tumors [2]. Normally, carcinogenic lung lesions are treated using surgery, radio-oncological methods, systemic chemotherapy or immune therapy. In addition to these methods, interventional radiology offers many new techniques such as radiofrequency ablation (RFA), microwave ablation and laser-induced thermotherapy (LITT) in order to treat lung lesions. These interventional techniques can be used for the treatment of lung tumors that are ≤3 cm in diameter and have ≤3 lesions in number; furthermore, these techniques provide local tumor control rates of more than 85%.

Planning & treatment

The relevance of ablation therapy, patient age and medical history should be considered for all patients before examination. Interventionalists should make a proper assessment of the scope and risks of the procedure before treatment. Patients' respiratory and physiological restrictions should be evaluated. Lung function analysis, respiratory flow measurement using spirometry and forced expiratory volume in 1 s measurements must be performed before the examination. Furthermore, lung perfusion, arterial blood gas evaluation and spiroergometry are required before the LITT procedure. Patient contraindications for the LITT procedure are: bleeding coagulopathy based on international normalized ratio >1.8; and platelet count <50,000/dl.

A number of small applicators are placed directly in the tumor using minimally invasive percutaneous puncture **(Figures 5.1 & 5.2)** [3]. The interventional procedure is usually performed under computed tomography (CT) guidance in contrast to MRI. CT imaging provides excellent contrast between tumor and lung parenchyma. It also ensures adequate estimation of the achieved coagulated volumes. In MRI, it is more difficult to detect pneumothorax or probe dislocation. Clinical problems associated with LITT therapy include pneumothorax and treatment probe dislocation; hence, MRI is not commonly suggested as a real-time imaging modality for the regular LITT procedure. Sufficient differentiation among

The puncture needle will be positioned under computed tomography control after disinfection of skin and regional analgesia.

lung parenchyma and tumor can be obtained using CT imaging data, and an adequate assessment of coagulation volume after LITT treatment can be ensured **(Figure 5.3)**. Usually, the LITT treatment procedure is easier to perform in more central lung lesions compared with peripheral lesions. There is always the risk of pneumothorax during or after the procedure; proper precautions should be taken by the procedural personnel to prevent pneumothorax during needle puncture.

Figure 5.1. Axial slice of computed tomography pre-laser-induced thermotherapy image showing pulmonary lesion 5 mm in diameter (arrow).

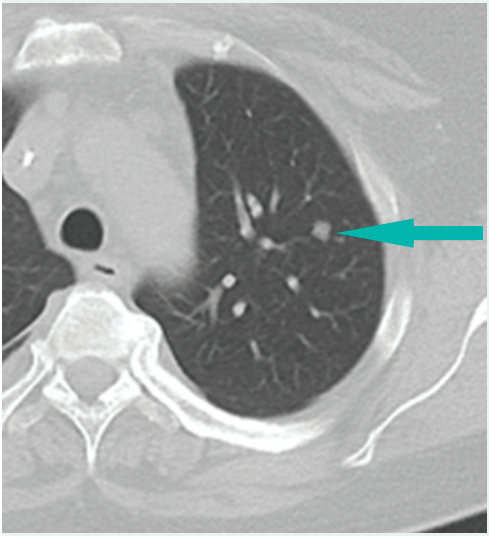

LITT treatment allows us to minimize damage to healthy lung tissues (around the involved area) and to destroy all suspected malignant cells inside the target tissue volume. As a result, maximum healthy lung tissues are preserved so that the vital functions of the organ can still be performed. Compared with surgery, LITT treatment offers the possibilities of repeated treatment options (repeated surgical procedures are usually difficult), follow-up suitability using MRI and improved quality of life [4]. In addition, there is also a cost benefit in comparison with other treatment options [5]. Treatment using LITT is difficult if the lesions are located in the areas of the lung that are difficult to access (e.g., behind the rib). In this situation, precise positioning of the applicator system is not possible using direct puncture, which is a disadvantage of the technique. During treatment, carbonization of the normal tissue is undesirable; normal lung parenchyma should always be preserved [3,6–8].

Complications of pulmonary LITT

Pulmonary ablation therapy has been considered as a safe and minimally invasive method compared with surgery, but associated procedure-related complications have to be expected. Complications may include pneumothorax, intraparenchymal hemorrhage, intrapleural hemorrhage, pleural effusion, tumor seeding and thermal damage to healthy tissue. Some common minor side effects, such as pain in the area of the puncture site, pleuritic pain, nausea, vomiting, moderate fever, fatigue and headache, are also quite frequent. The treatment effectiveness usually depends on the work experience of the interventionalist and team members, as well as the

Figure 5.2. Computed tomography axial section demonstrates puncture site with needle (arrow) during laser-induced thermotherapy.

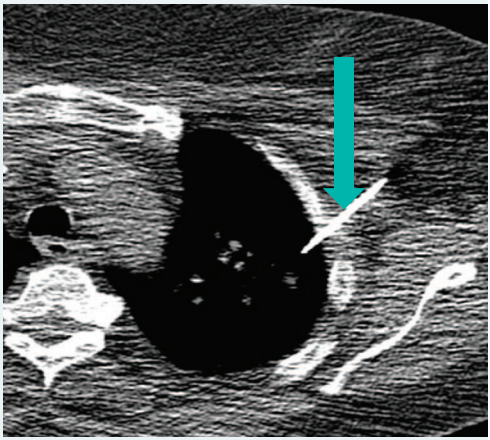

duration or amount of energy used for the treatment. The desired temperature for normal LITT is approximately 50–55°C. Protein denaturation takes place within a few seconds for temperatures exceeding 60°C [101]. It is necessary to control the complete procedure using real-time monitoring methods such as CT image guidance in order to achieve the desired result.

Results

We reviewed seven articles published from 2003 to 2012, which include 86 patients and 65 specimens obtained directly from the lungs of the patients **(Table 5.1)**. The number of patients in these articles varied from 10 to 48, and the treatment of choice was LITT. Primary or metastatic pulmonary tumors were the pathologies involved in these articles. The reported overall treatment outcome was good in all articles and no major complications were reported in these studies. Hoffmann *et al.* assessed the effect of temperature on tissue coagulation during laser ablation using the *ex vivo* lung tumor model [9]. The authors concluded that applied temperature during LITT has a direct effect on pulmonary tumor coagulation. Koch *et al.* also used the *ex vivo* model and compared temperature diffusion using one and two treatment applicators during thermal ablation [10]. The authors found that there was a significant increase in the achieved temperature in the tissues using two laser applicators.

Hegenscheid *et al.* analyzed induced early vascular changes in treated lung tumors followed by LITT and predicted the technical success rate of the therapy using LITT with CT perfusion [11]. The authors concluded that CT perfusion after LITT showed vascular changes and this technique was useful for evaluating the success rate of the therapy. Vogl *et al.* performed a comparative study with 20 patients using LITT and RFA [12]. The authors concluded that both therapies were safe and without any major complications. In another study by Vogl *et al.*, the authors included 30 patients and documented that percutaneous LITT of lung tumors allowed complete ablation of lung carcinomas or

For LITT, an irrigated application system was developed that diffuses laser energy in a predefined volume and thus produces homogeneous energy dissipation at its tip. New applicator systems comprise a scattering dome applicator, a sheath system and a thermally stable protective catheter so that the LITT applicator remains sterile and can be flexibly positioned.

metastases with a low complication rate [13]. A study by Diederich and Hosten showed that LITT and RFA were a safe and minimally invasive method for the treatment of pulmonary carcinoma and/or pulmonary metastasis [14]. Similar results were obtained in the study by Weigel *et al.* [15]. Hosten *et al.* conducted research in ten patients using a miniaturized applicator system in order to determine the effect of LITT treatment on pulmonary tumors [3]. They found that LITT treatment was a safe and acceptable procedure.

Figure 5.3. Cross-sectional image of computed tomography thorax demonstrating scar formation after laser-induced thermotherapy treatment in the lung (20 × 25 mm in diameter; see arrow).

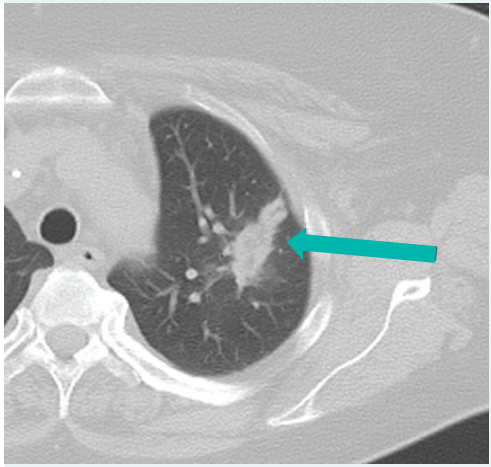

Conclusion

Surgery is the treatment of choice for primary or metastatic lung neoplasms. If surgical resection of the lesion is not possible, other treatment methods such as LITT, RFA or microwave ablation can be used to treat the pulmonary lesions (primary or metastatic tumors). LITT was first used as a palliative therapy of tumors but, during the years, it has become an acceptable choice of therapy against lung tumors because it has many clinical advantages such as high patient safety, minimally invasive technique, repeatability of treatment, outpatient therapy management, improved long-term survival and effective local tumor control. A high tendency of the malignant cells to spread into surrounding tissues limits the achievement of complete cure in many situations. Recurrence may occur after incomplete removal or incomplete ablation of the lesion(s), which is considered as another limiting parameter. The combination of surgery and neoadjuvant ablation treatment methods sometimes turns inoperable lesions into curative ones. Focused therapy makes it possible to destroy treated lesions and to preserve healthy lobes of the lung. LITT treatment offers better quality of life and symptomatic relief for the patients. We consider LITT to be a major treatment modality in the complex area of lung oncology. Treatment outcome is determined by appropriate patient selection, evaluation of the procedure before treatment, awareness of the limitations of the available therapeutic ablative tools, and knowledge of tumor characteristics and metastatic spread. In addition to other modalities, such as surgery, radiotherapy or chemotherapy, ablative therapies have a major role in lung tumor treatment.

Table 5.1. Published articles and associated information related to the treatment of pulmonary tumors using laser-induced thermotherapy.

Study (year)	Patients (n)	Pathology	Procedure	Outcome	Complications	Notes	Ref.
Hoffmann *et al.* (2012)	17	NSCLC	LITT	Good	Not mentioned	The isolated human lung perfusion model provided a possible method to evaluate *ex vivo* interrelationships of temperature, time of temperature exposure and resulting coagulation	[9]
Koch *et al.* (2011)	48	NSCLC	LITT One and two applicators	Good	Not mentioned	Use of two laser applicators increased the achieved temperature significantly	[10]
Hegenscheid *et al.* (2010)	12	Pulmonary metastases	LITT	Good	Not mentioned	Tumors with perfusion measurements showed no vascular changes after therapy indicating progressive disease	[11]
Vogl *et al.* (2004)	20 (RFA) 34 (LITT)	Pulmonary tumors	RFA versus LITT	Acceptable tumor control rate	Low complication rate	Safe thermal ablation is possible using LITT for the treatment of pulmonary metastases	[12]
Vogl *et al.* (2004)	30	Primary and secondary lung tumors	LITT	Good	Low complication rate	Procedure was defined for patients with no more than five metastases and up to 3 cm in size	[13]
Diederich and Hosten (2004)	Not mentioned	Metastases of the lung	RFA and LITT	Good	Serious complications were rare	Tumor ablation is a riskless option for a high percentage of inoperable lung metastases	[14]
Hosten *et al.* (2003)	10	Lung metastases	LITT	Good	Not mentioned	Complete ablation of the lesion is possible in suitable patients	[3]

LITT: Laser-induced thermotherapy; NSCLC: Non-small-cell lung cancer; RFA: Radiofrequency ablation.

Financial & competing interests disclosure

The authors have no relevant affiliations or financial involvement with any organization or entity with a financial interest in or financial conflict with the subject matter or materials discussed in the manuscript. This includes employment, consultancies, honoraria, stock ownership or options, expert testimony, grants or patents received or pending, or royalties.

No writing assistance was utilized in the production of this manuscript.

Summary.

- Laser-induced thermotherapy (LITT) is a valid alternative to surgery, radiotherapy or chemotherapy in the treatment of pulmonary lesions.
- LITT is a safe, noninvasive technique to improve outcome, with better local tumor control compared with surgery, increased survival rate and relief of clinical symptoms.
- LITT can be used for the treatment of lung tumors that are ≤3 cm in diameter and ≤3 lesions in number.
- LITT procedures provide high patient safety, minimally invasive technique, outpatient therapy management, repeatability of treatment, improved long-term survival and effective local tumor control.

References

1 Murray CJL, Lopez AD. Mortality by cause for eight regions of the world: Global Burden of Disease Study. *Lancet* 349(9061), 1269–1276 (1997).

2 Kumar V, Abbas, AK, Fausto N, Mitchell R. The lung. In: *Robbins Basic Pathology (8th Edition).* Mosby/ Saunders, Elsevier, USA (2007).

3 Hosten N, Stier A, Weigel C. Laser-induced thermotherapy (LITT) of lung metastases: description of a miniaturized applicator, optimization, and initial treatment of patients. *Fortschr Rontgenstr* 175, 393–400 (2003).

4 Liapi E, Geschwind JF. Transcatheter and ablative therapeutic approaches for solid malignancies. *J. Clin. Oncol.* 25(8), 978–986 (2007).

5 Vogl TJ, Naguib NNN, Lehnert T, Nour-Eldin NEA. Radiofrequency, microwave and laser ablation of pulmonary neoplasms: clinical studies and technical considerations. *Eur. J. Radiol.* 77(2), 346–357 (2011).

6 Ishibashi H, Takahashi H, Ashino Y. Radiofrequency ablation for metastatic lung tumor. *Kyobu Geka* 56, 119–123 (2003).

7 Jolesz FA, Bleier AR, Jakab P, Ruenzel PW, Huttl K, Jako GJ. MR imaging of laser tissue interactions. *Radiology* 168, 249–253 (1988).

8 Lee J, Jin G, Goldberg S *et al.* Percutaneous radio-frequency ablation for inoperable non-small cell lung cancer and metastases: preliminary report. *Radiology* 230, 125–134 (2004).

9 Hoffmann CO, Rosenberg C, Linder A, Hosten N. Residual tumor after laser ablation of human non-small-cell lung cancer demonstrated by *ex vivo* staining: correlation with invasive temperature measurements. *MAGMA* 25(1), 63–74 (2012).

10 Koch F, Vietze A, Laskowski U, Ritter C, Linder A, Hosten N. *Ex-vivo* human lung tumor model: use for temperature measurements during thermal ablation of NSCLC. *Rofo* 183(3), 251–259 (2011).

11 Hegenscheid K, Behrendt N, Rosenberg C *et al.* Assessing early vascular changes and treatment response after laser-induced thermotherapy of pulmonary metastases with perfusion CT: initial experience. *AJR Am. J. Roentgenol.* 194(4), 1116–1123 (2010).

12 Vogl TJ, Straub R, Lehnert T *et al.* Percutaneous thermo-ablation of pulmonary metastases. Experience with the application of laser-induced thermotherapy (LITT) and radiofrequency ablation (RFA), and a literature review. *Rofo* 176(11), 1658–1666 (2004).

13 Vogl TJ, Fieguth HG, Eichler K *et al.* Laser-induced thermo-therapy of lung metastases and primary lung tumors. *Radiologe* 44(7), 693–699 (2004).

14 Diederich S, Hosten N. Percutaneous ablation of pulmonary tumors: state-of-the-art 2004. *Radiologe* 44(7), 658–662 (2004).

15 Weigel C, Schuchmann S, Kirsch M, Mensel B, Hosten N. Percutaneous thermoablation of lung metastases. Indication, performance, initial results, and imaging findings. *Radiologe* 44(5), 491–499 (2004).

Website

101 Vogl TJ, Mack MG, Straub R *et al.* MR-guided laser induced thermotherapy (LITT) of malignant liver and soft tissue tumors. For lasermedicine. http://radiologie-uni-frankfurt.de/sites/radiologie-uni-frankfurt.de/content/e43/e2321/e2323/litt_eng.pdf