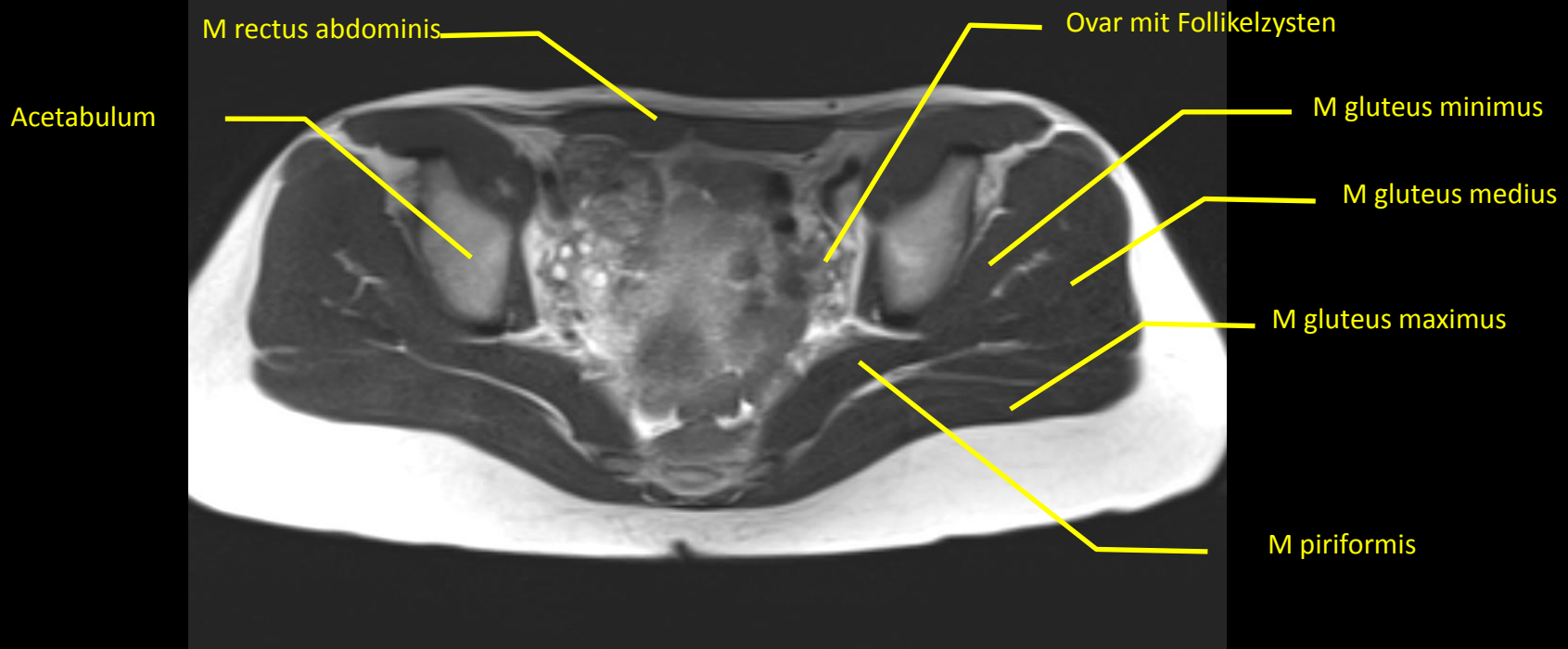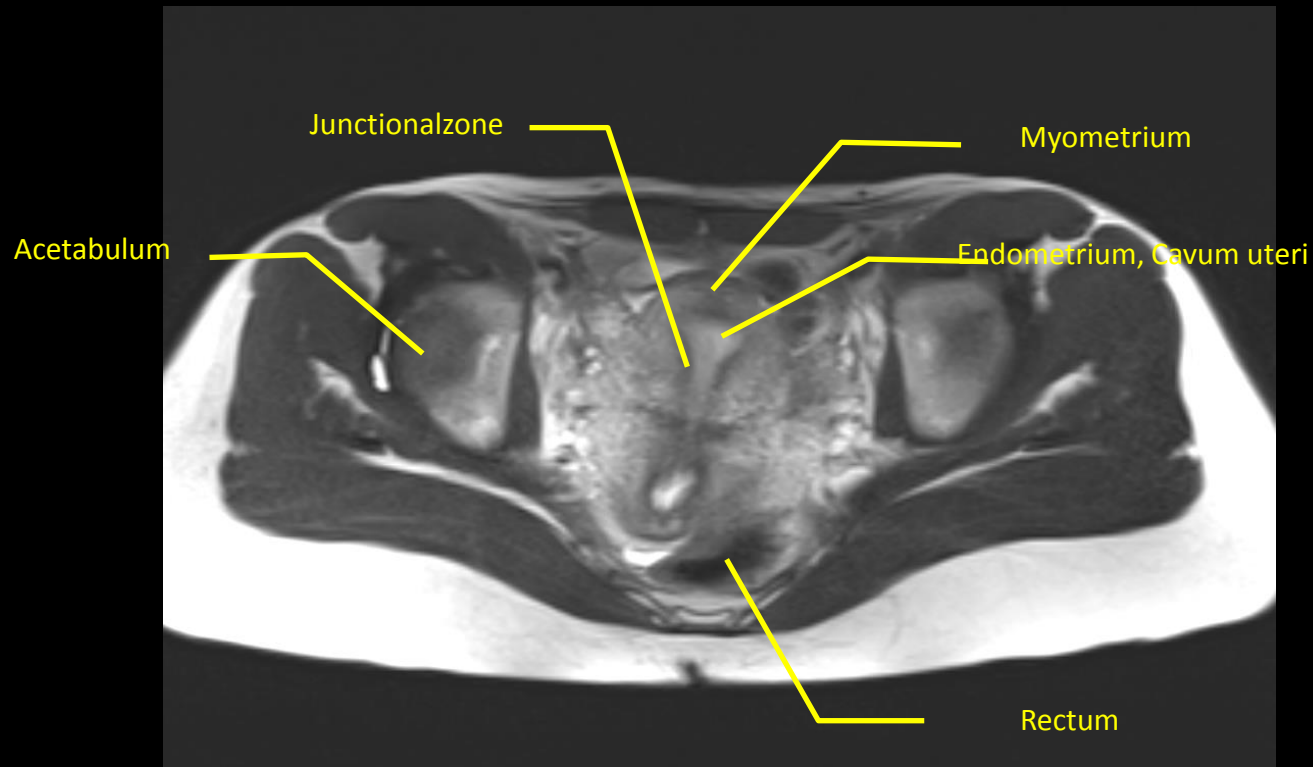
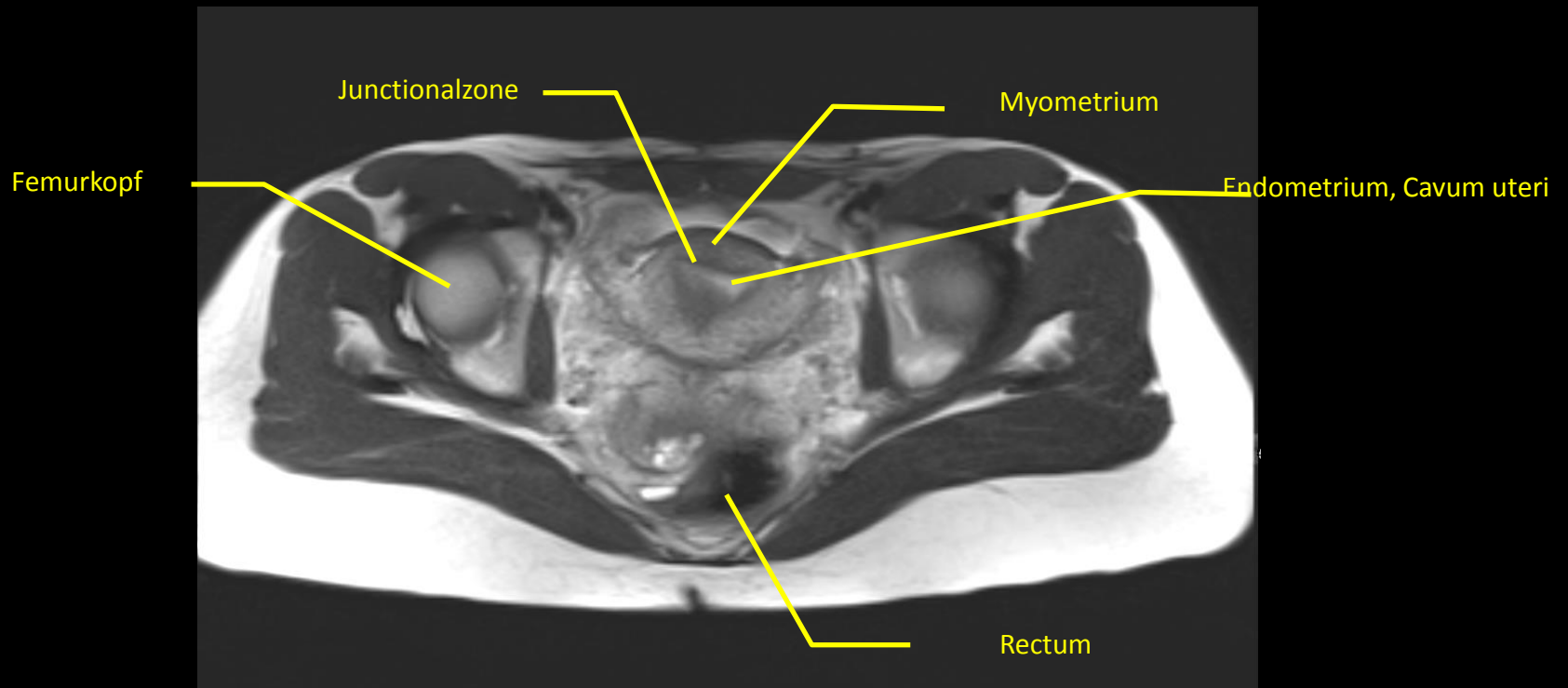


T2 - Transversal



T2 - Transversal



T2 - Transversal

M iliopsoas

M sartorius

Junctionalzone,
Tangential
angeschnitten

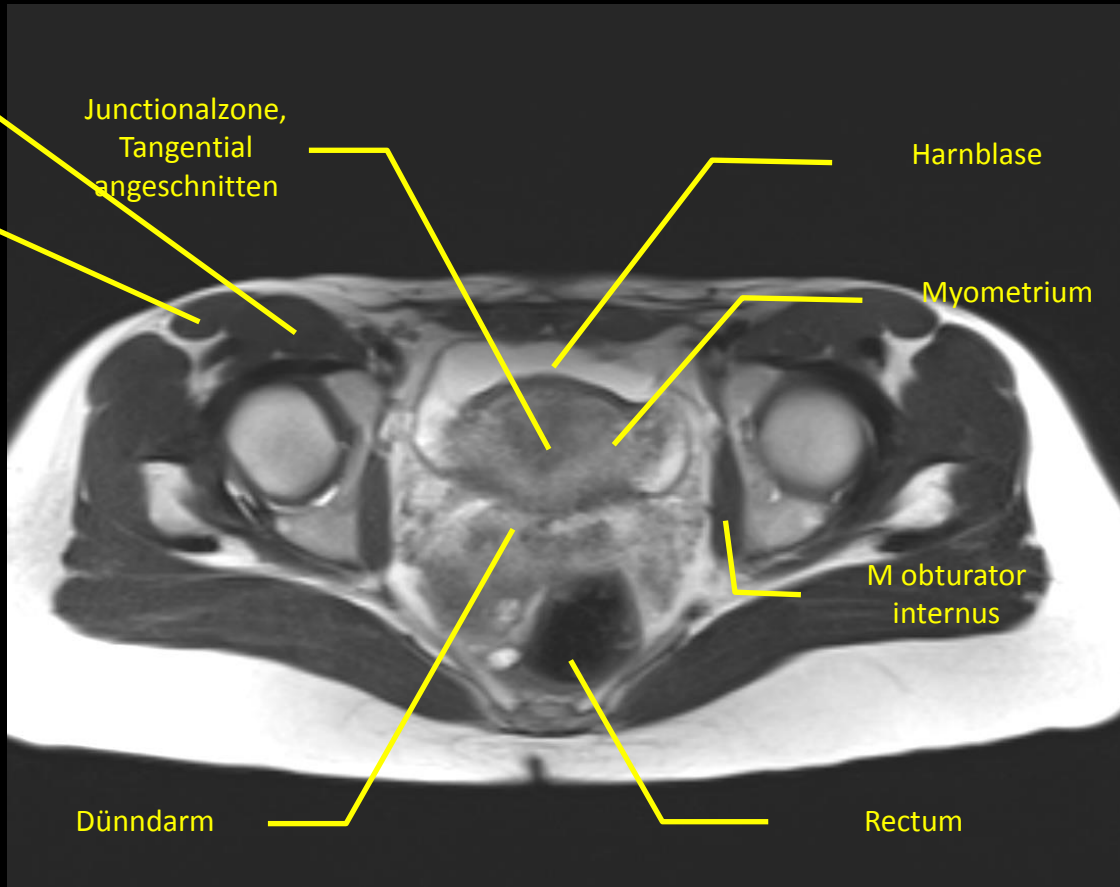
Harnblase

Myometrium

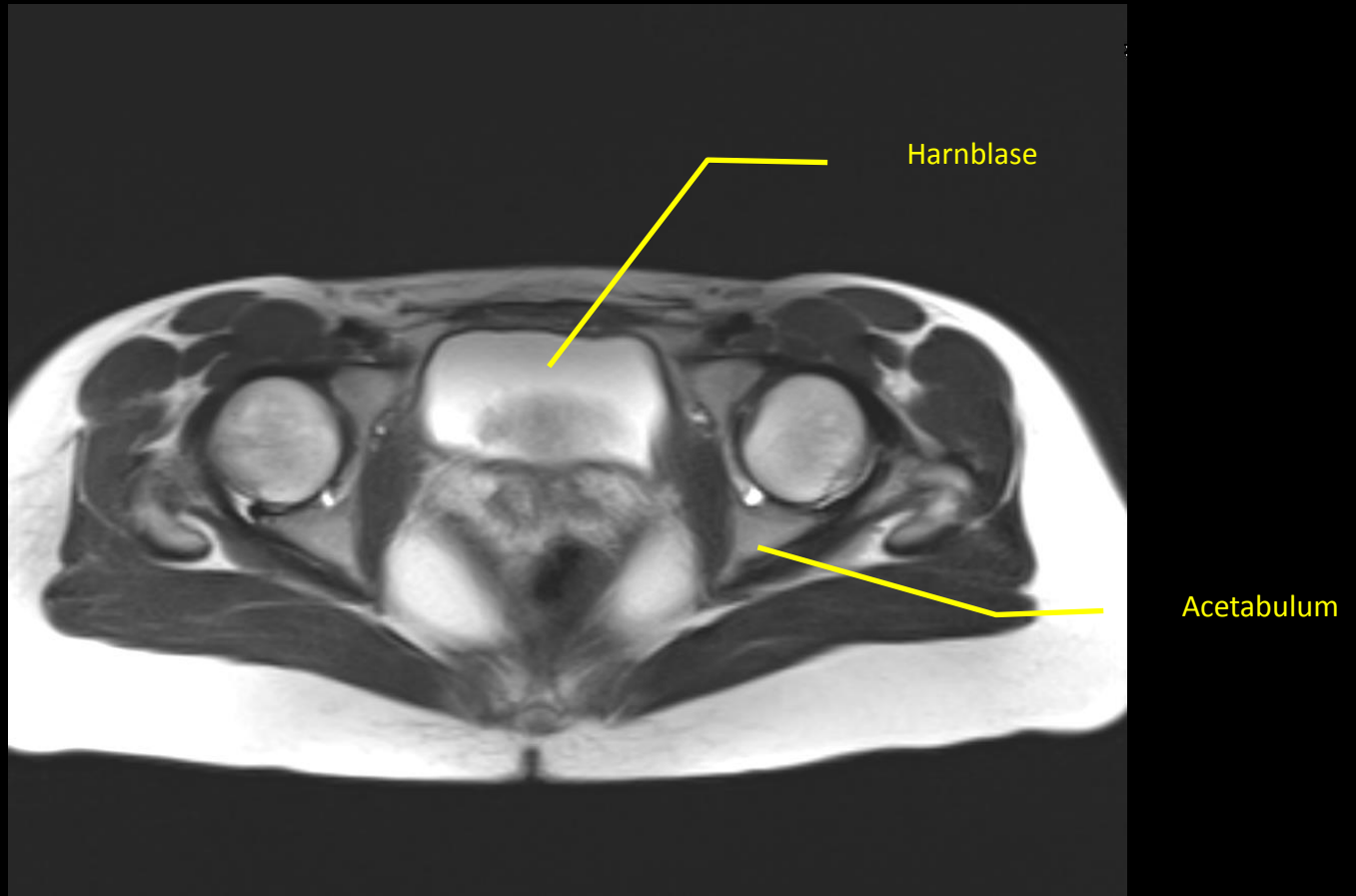
M obturator
internus

Dünndarm

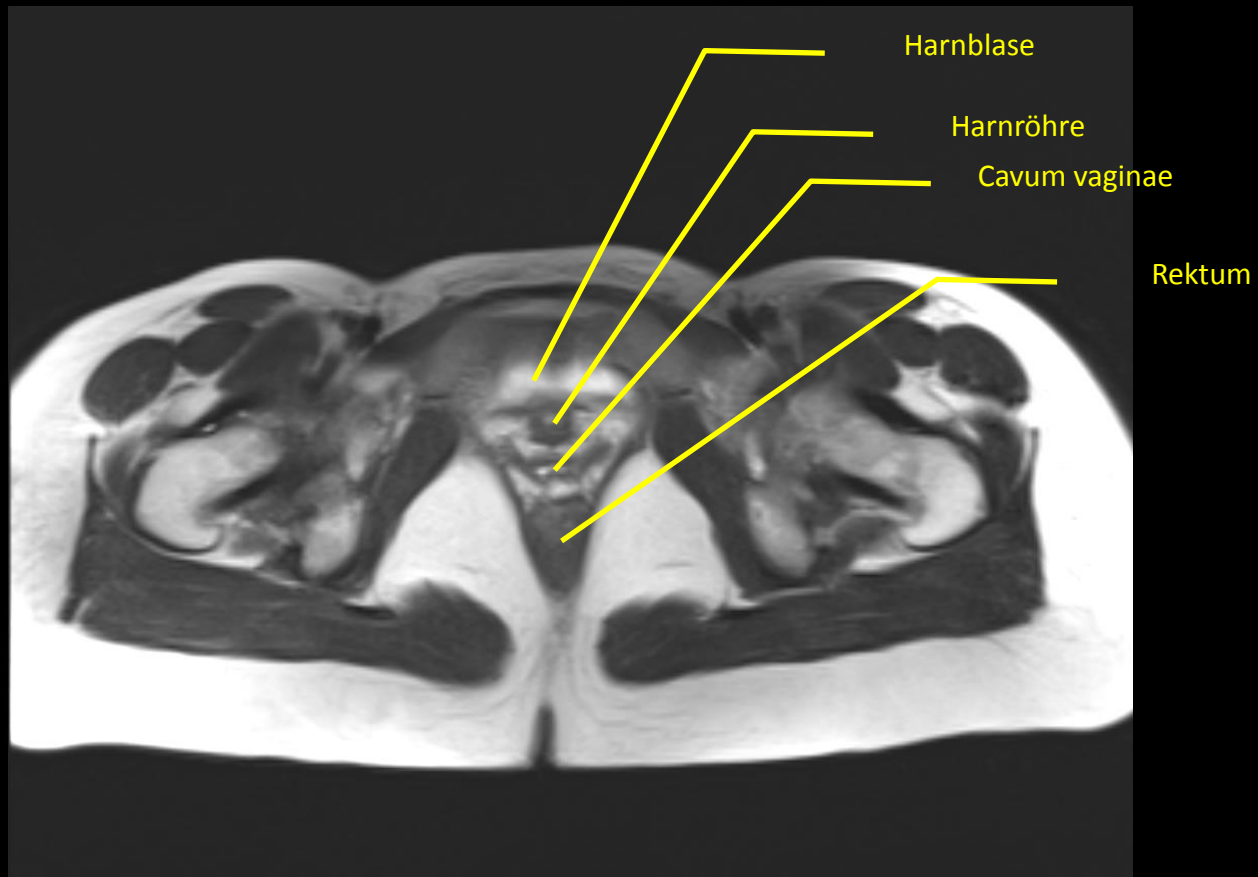
Rectum



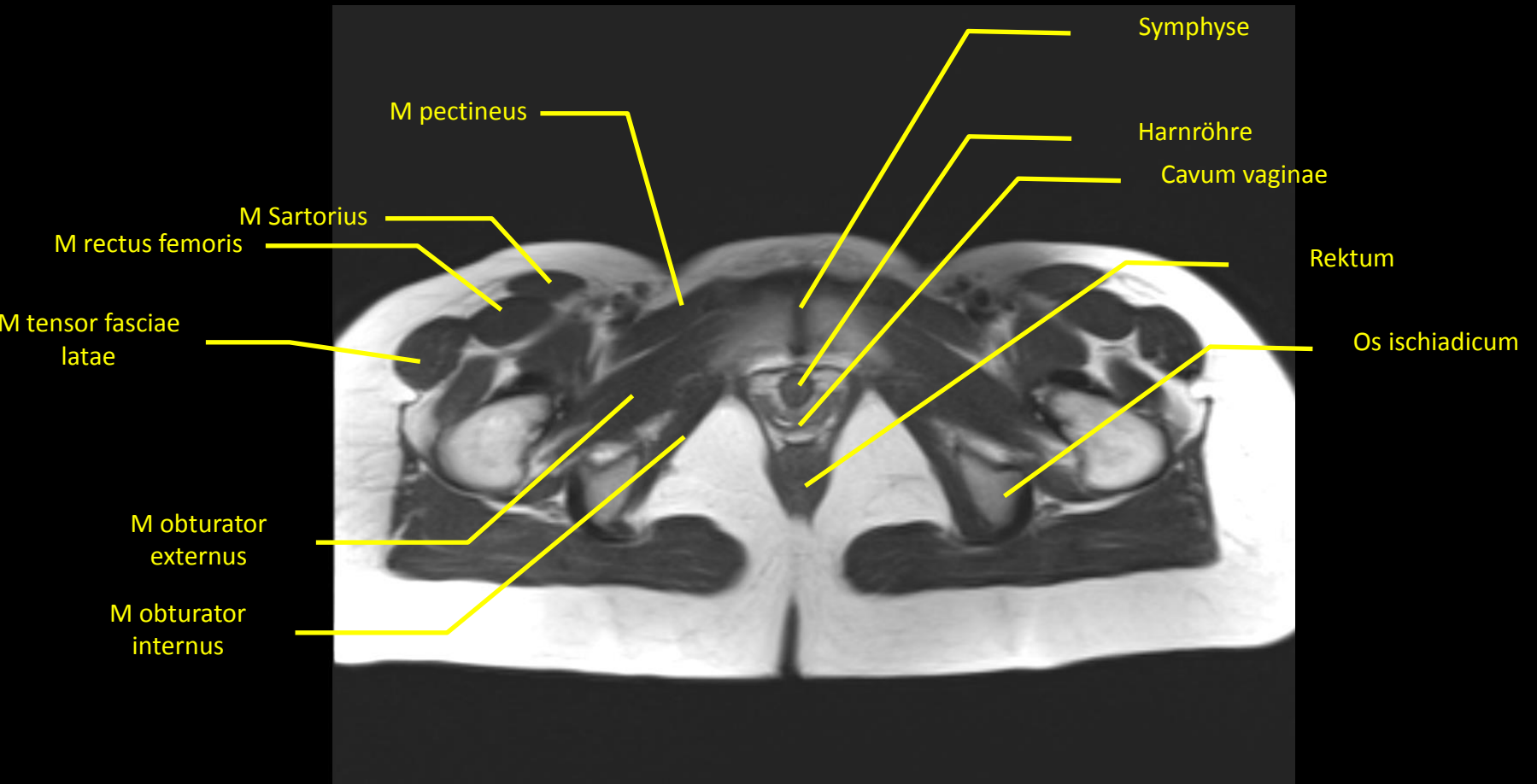
T2 - Transversal



T2 - Transversal



T2 - Transversal



T2 - Transversal

M vastus lateralis

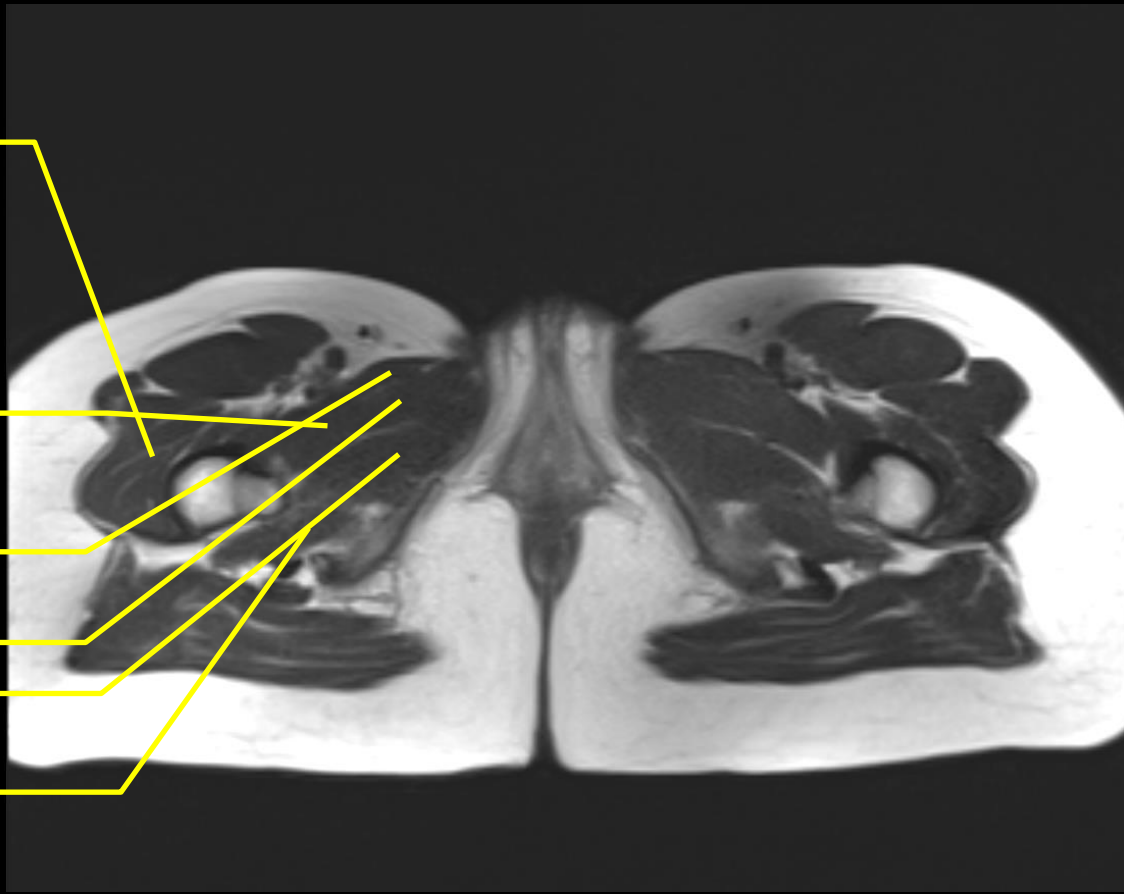
M pectineus

M add longus

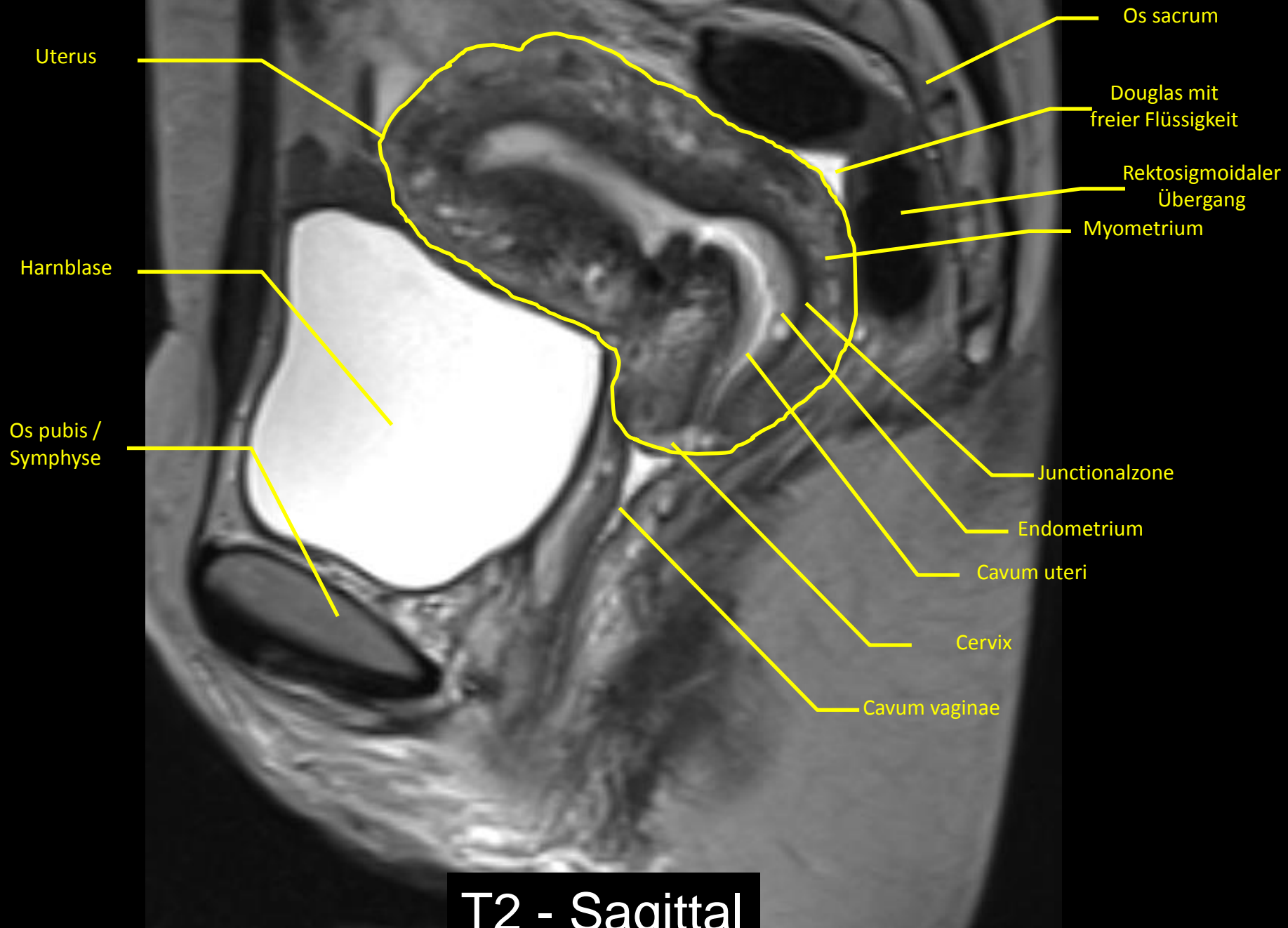
M add brevis

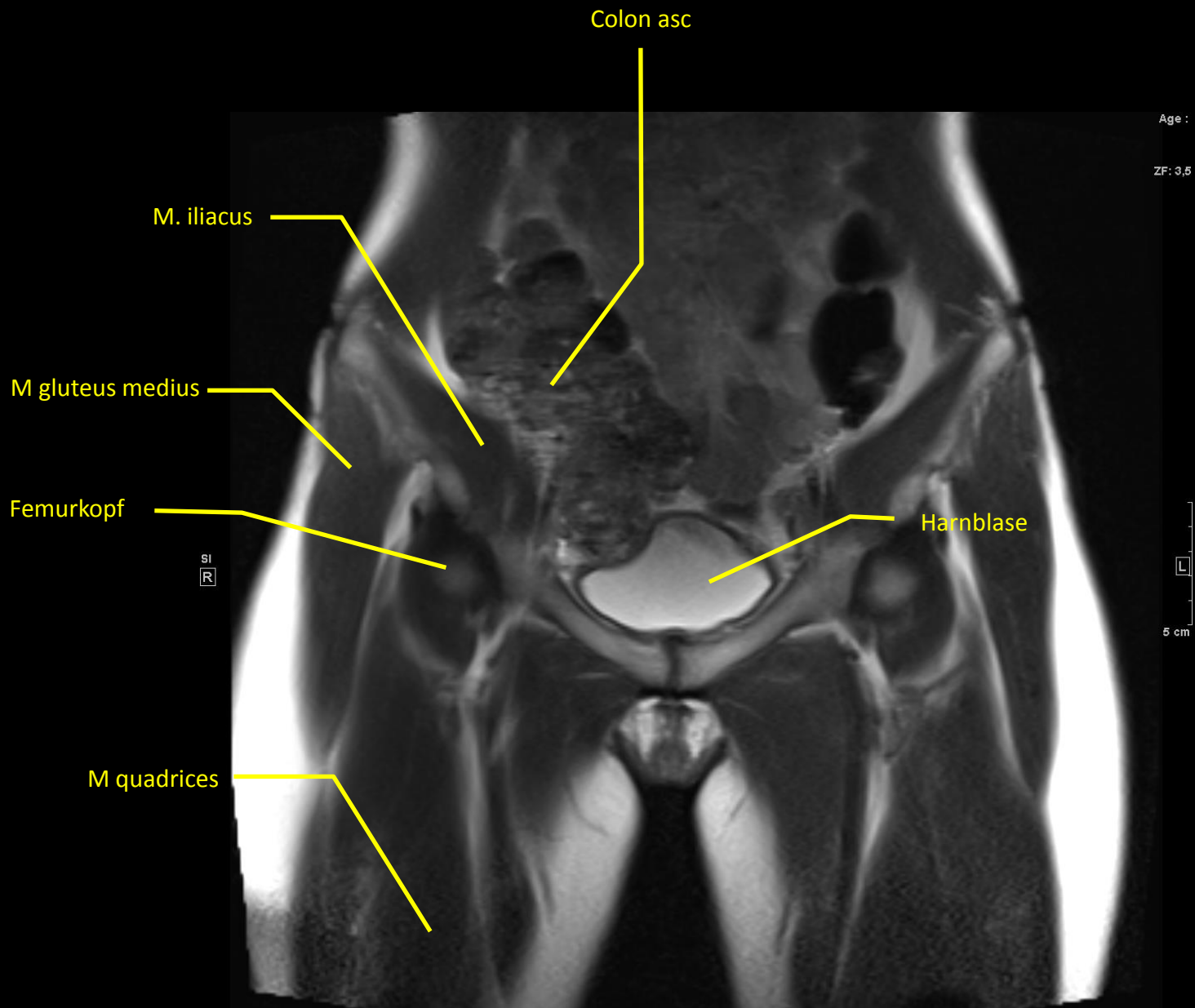
M add magnus

M quadratus

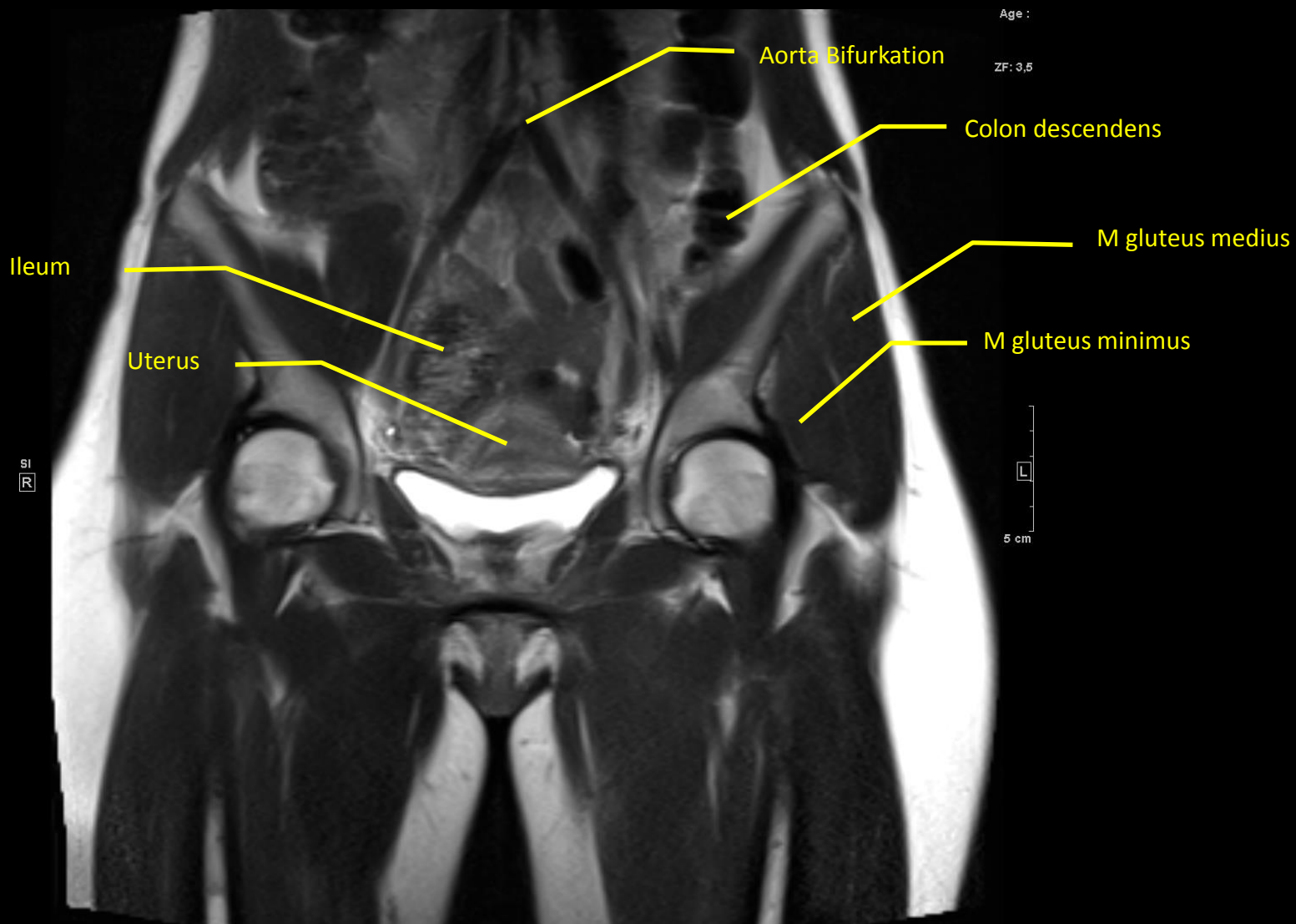


T2 - Transversal

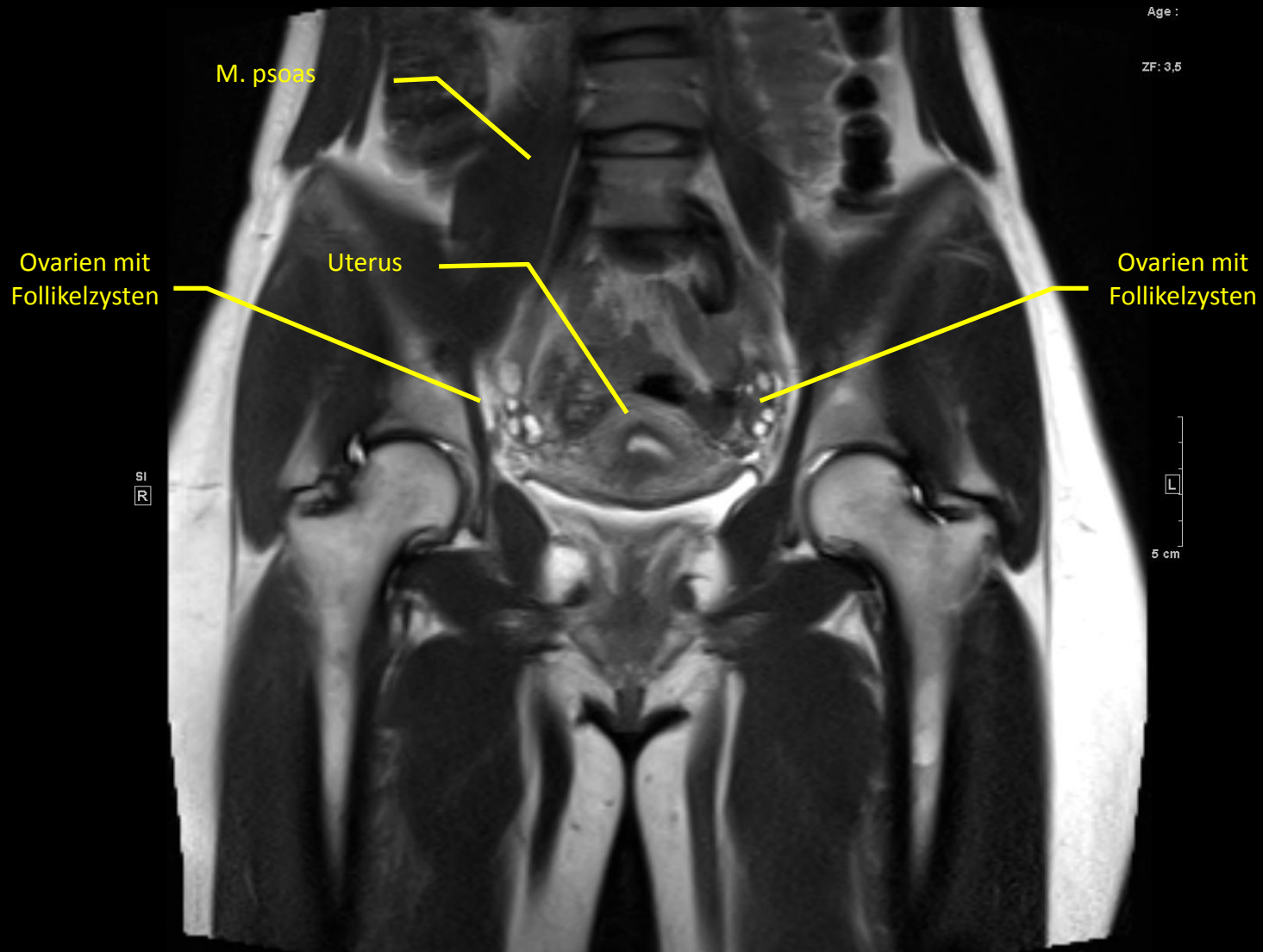




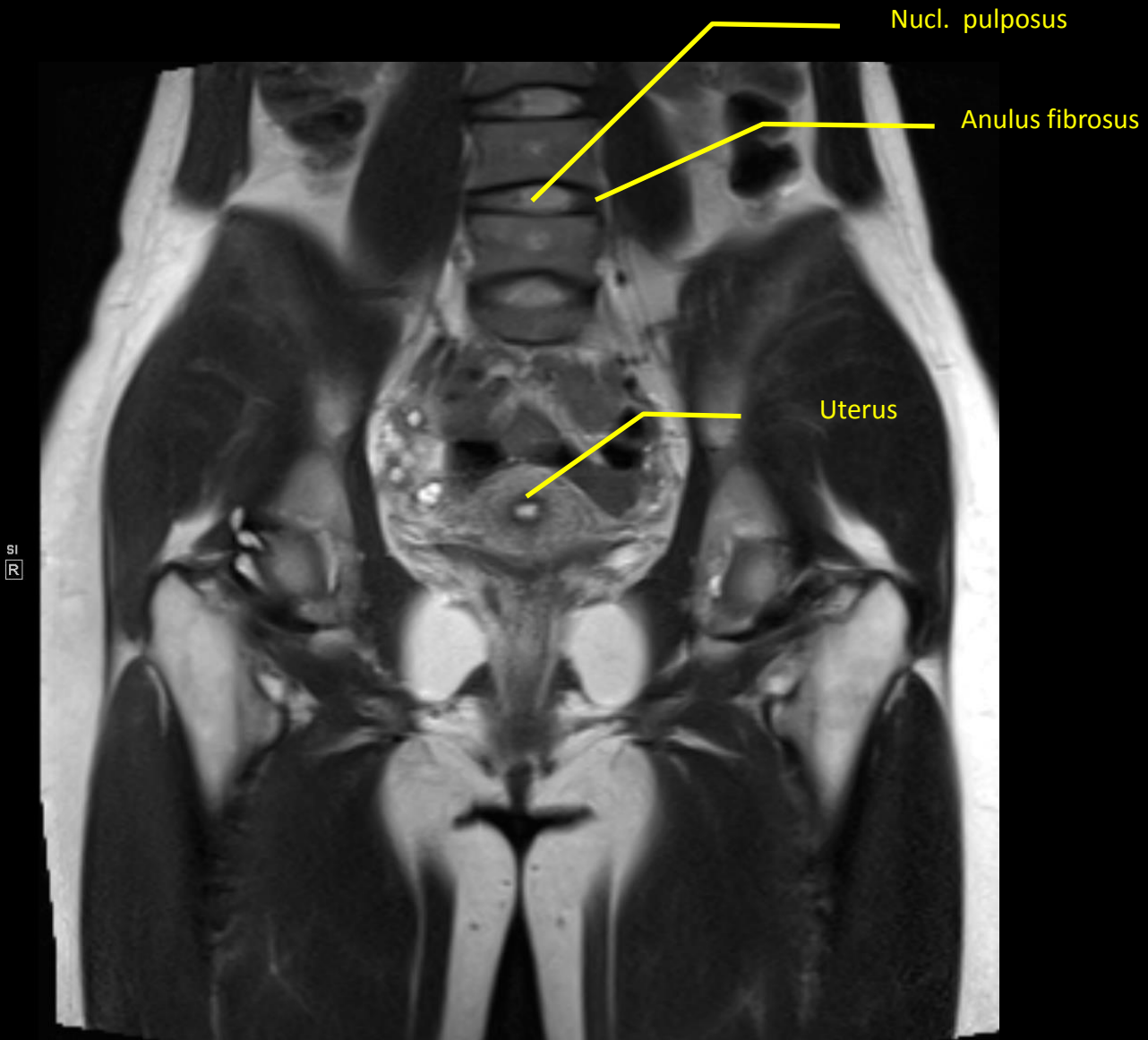
T2 - Coronal



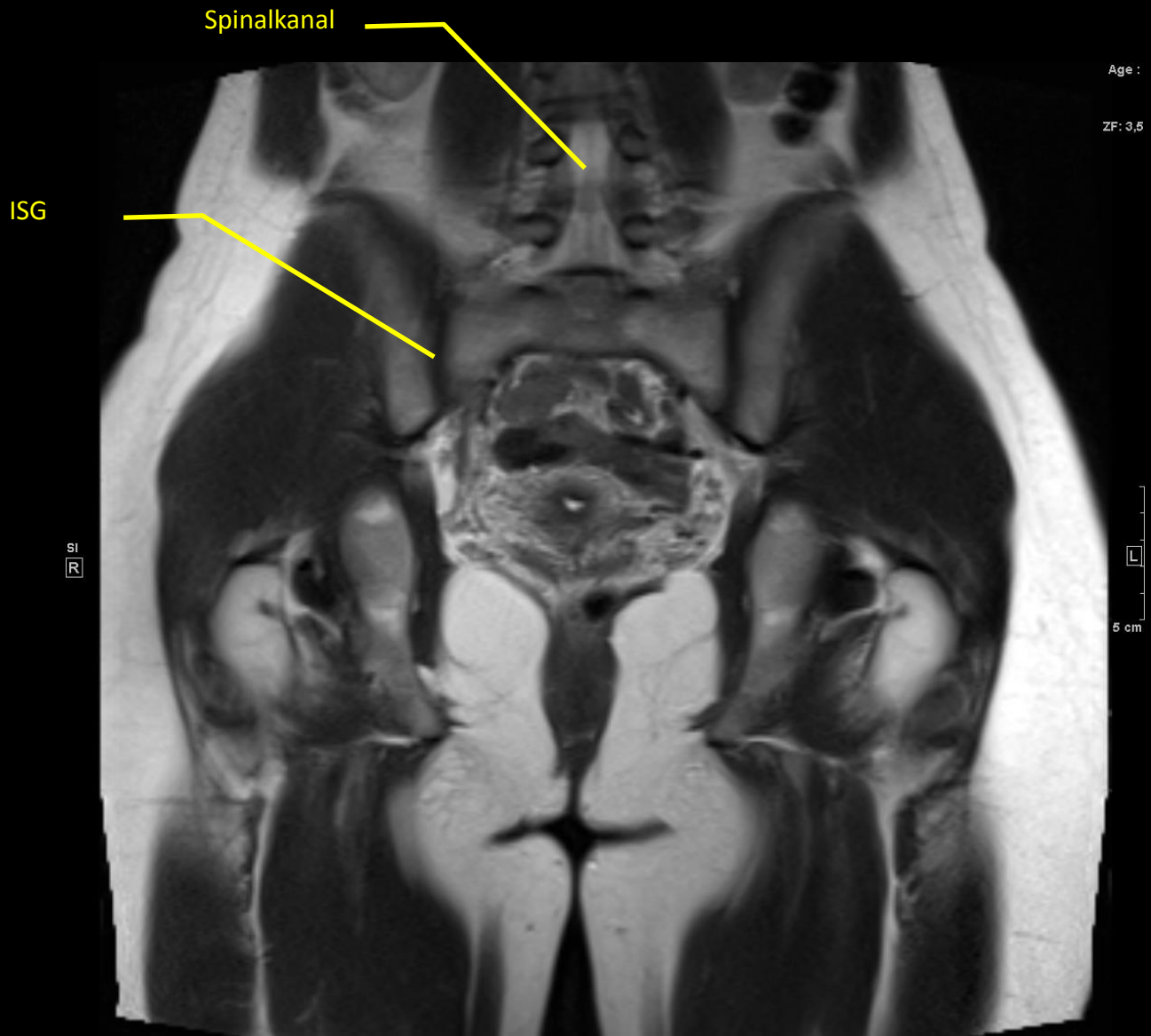
T2 - Coronal



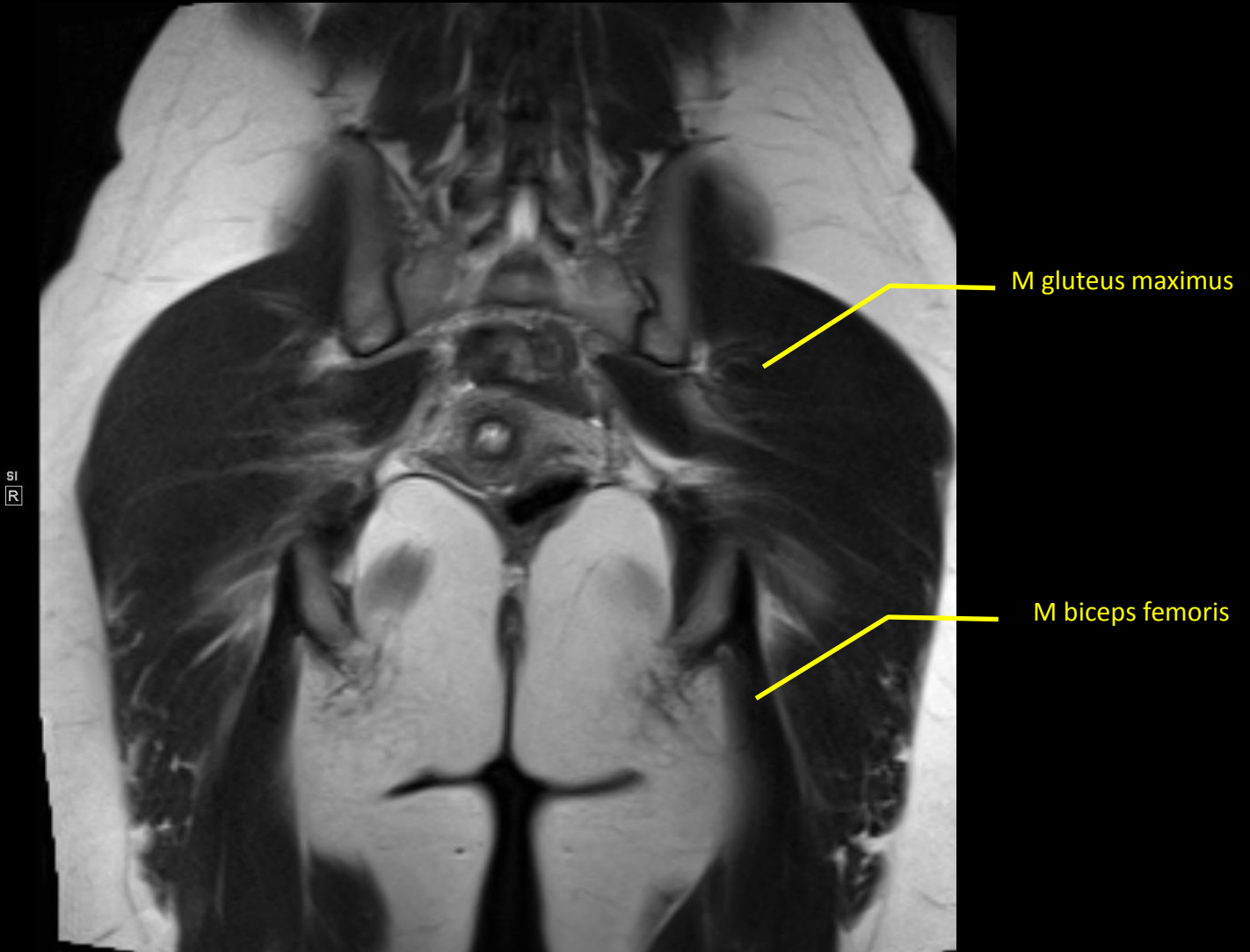
T2 - Coronal



T2 - Coronal



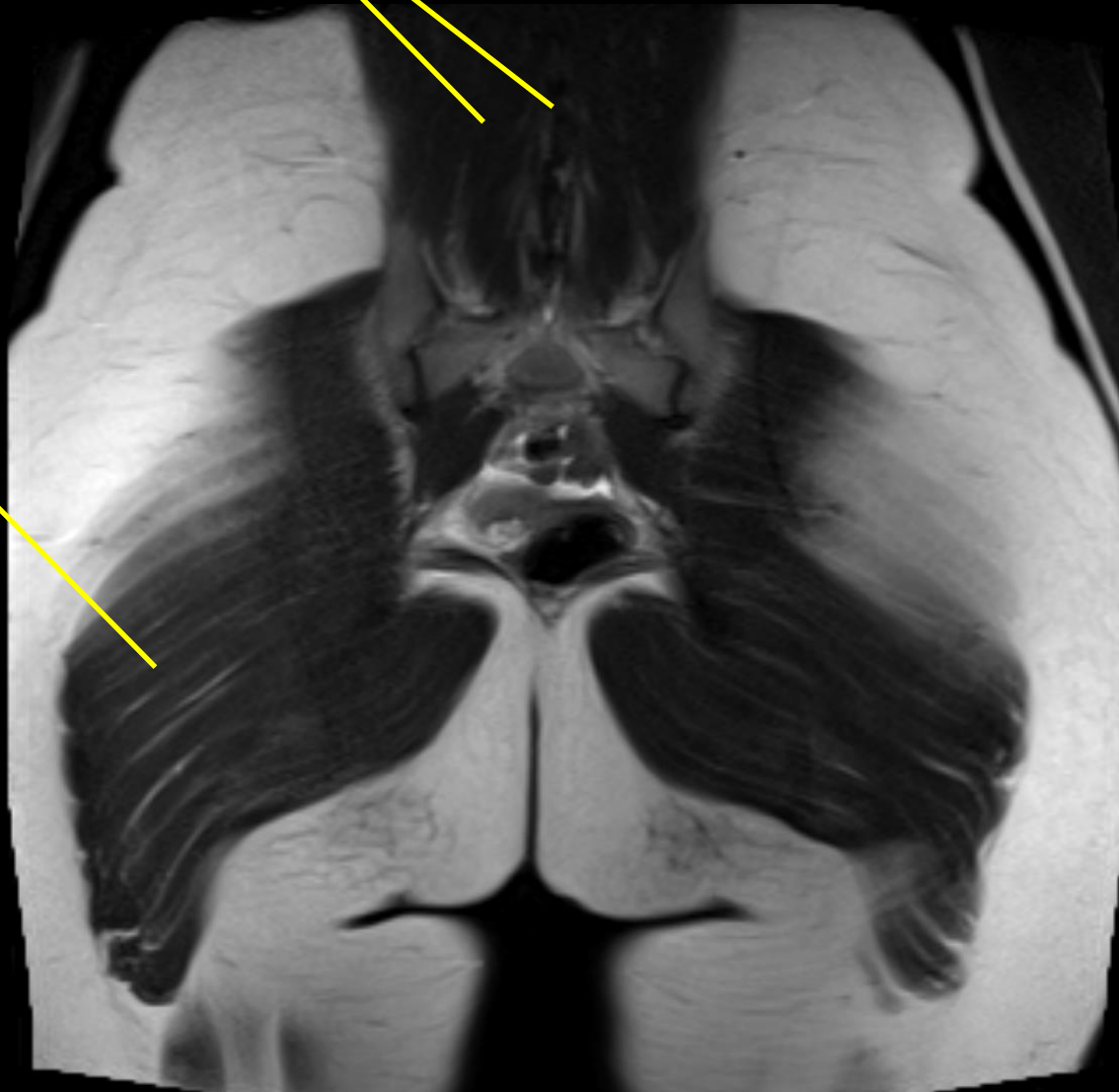
T2 - Coronal



T2 - Coronal

Dornfortsätze

Autochtone
Rückenmuskulatur



Age :

ZF: 3,5

M gluteus maximus

SI
R

L

5 cm

T2 - Coronal