

Stephan Zangos
Katrin Eichler
Jörn O. Balzer
Ralf Straub
Renate Hammerstingl
Christopher Herzog
Thomas Lehnert
Mathias Heller
Axel Thalhammer
Martin G. Mack
Thomas J. Vogl

Large-sized hepatocellular carcinoma (HCC): a neoadjuvant treatment protocol with repetitive transarterial chemoembolization (TACE) before percutaneous MR-guided laser-induced thermotherapy (LITT)

Received: 26 August 2005
Revised: 3 May 2006
Accepted: 22 May 2006
© Springer-Verlag 2006

S. Zangos (✉) · K. Eichler ·
J. O. Balzer · R. Straub ·
R. Hammerstingl · C. Herzog ·
T. Lehnert · M. Heller ·
A. Thalhammer · M. G. Mack ·
T. J. Vogl
Department of Diagnostic and
Interventional Radiology,
University Hospital Frankfurt,
Johann Wolfgang Goethe-University,
Theodor-Stern-Kai 7,
60590 Frankfurt/Main, Germany
e-mail: Zangos@em.uni.frankfurt.de
Tel.: +49-69-63017277
Fax: +49-69-63017258

Abstract This study aims to evaluate the efficacy and safety of a neoadjuvant treatment protocol with repeated transarterial chemoembolization (TACE) before MR-guided laser-induced thermotherapy (LITT) for large-sized hepatocellular carcinomas (HCC). Repeated TACE (mean, 3.5 treatments per patient) was performed in 48 patients with neoadjuvant intention (the largest lesion was between 50 and 80 mm in diameter, and there were no more than five lesions). For the TACE treatment, we used 10 mg/m² mitomycin, 10 ml/m² Lipiodol and microspheres. The tumor volume was measured by MRI. Lipiodol retention of the tumors was evaluated with CT. After the diameter of the tumors had decreased to less than 50 mm, the patients were treated with MR-guided LITT 4 to 6 weeks

after embolization. Repeated TACE reduced the tumor size in 32 patients (66.7%), forming the basis for performing MR-guided LITT procedures. These patients received one to four laser treatments (mean, 1.9 per patient) for tumor ablation, resulting in a median survival of 36.0 months after the first treatment. For the remaining patients, no reduction in tumor size was achieved in 12 patients and disease progression in 4 patients. Neoadjuvant TACE appears to be an effective treatment of large-sized HCC, which extends the indication for MR-guided LITT.

Keywords Lasers · Interstitial therapy · Liver · Interventional procedures · Liver neoplasms · Therapy · Chemotherapeutic embolization

Introduction

Hepatocellular carcinoma (HCC) is the most common solid-organ malignancy worldwide, affecting males with a high prevalence in sub-Saharan Africa, southeastern Asia and south Europe [1]. Moreover, recent data suggest that the incidence and mortality of HCC in Western nations is on the rise, and HCC is currently the leading cause of death among cirrhotic patients [1–3]. Parallel to these epidemiologic changes, the increased surveillance of patients at risk and advances in hepatic imaging of HCC have led to an increasing number of patients who need to be treated.

Liver resection and orthotopic liver transplantation (OLT) are potentially curative therapeutic options. However, in many countries the absence of donors for OLT

results in long waiting lists. Likewise, percutaneous ablative treatments [3, 4] such as percutaneous ethanol injection (PEI) [5, 6], MR-guided laser-induced thermotherapy (LITT) [7, 8], microwave coagulation [9, 10] or radiofrequency ablation [11, 12] are more frequently used techniques with curative potential.

However, most HCC patients are unresectable at diagnosis because of multicentricity, large tumor size or a poor hepatic functional reserve due to pre-existing cirrhosis, or they are not transplantable because of a too advanced tumor stage or severe co-morbidity [13]. Therefore, transarterial chemoembolization (TACE) is widely used as a non-surgical palliative local therapeutic option for the treatment of HCC [1, 14–19]. However, tumor cells may remain viable after TACE treatment, and complete tumor necrosis

occurred only in 16.9% of the patients [20]. As a result, tumor ablation is still a necessary component in the treatment of large tumors as a possible locally curative therapy after effective TACE treatment.

The purpose of our study was to evaluate the efficacy and safety of a neoadjuvant treatment protocol with repeated transarterial chemoembolization (TACE) before laser-induced thermotherapy (LITT) in patients with large-sized unresectable HCC.

Materials and methods

Patients

A total of 48 patients (10 females and 38 males) ranging in age from 50.1 to 81.2 years (mean age, 67.7 years) with large unresectable hepatocellular carcinoma were treated with repetitive TACE treatments ($n=195$) with neoadjuvant intention. The goal of the neoadjuvant treatment was to transfer primary unresectable patients with large liver tumors into an ablative situation by shrinking the tumor size.

The study was approved by the institutional review board. The patients were included by consensus (T.V. and S.Z.) in compliance with our inclusion and exclusion criteria between January 2000 and January 2004.

Inclusion and exclusion criteria

The indications for the combined neoadjuvant protocol of TACE and LITT were unresectable HCC evaluated on contrast-enhanced MRI studies (Table 1). The maximum diameters of the target liver lesions were between 50 and 80 mm. Treatment was limited to patients with no more than five tumors and no extra-hepatic spread. Two of the five metastases were allowed to have a diameter between 50 and 80 mm; the other lesions had to be smaller than 50 mm.

Monitoring of laboratory values, such as the white blood cells, elementary bodies, hemoglobin, bilirubin, creatinine, transaminases, choline esterase and coagulation, was required before each treatment. For every patient, the Child's classification was ascertained. Contraindications to our combined TACE and LITT protocol were poor performance status or poor hepatic function (Child-Pugh class C), nutritional impairment, extensive neoplastic ascites, high serum bilirubin level (>3 mg%) and renal failure (serum creatinine >2 mg%).

Partial or complete thromboses of the main portal vein, cardiovascular and respiratory failure were further exclusion criteria for the procedure. The patients had to be in good mental condition and had to be able to provide their own consent to ensure adequate treatment compliance.

Table 1 Inclusion and exclusion criteria for the combined treatment protocol

Inclusion criteria

- Unresectable liver tumors
- Contraindication for surgery
- Maximum of five liver lesions
- Maximum tumor size: 50–80 mm ($n=2$)
- No extrahepatic tumor manifestation

Exclusion criteria

- Extrahepatic tumors
- Poor performance status (Karnofsky-Index <50)
- Poor liver functions (serum albumin <2.0 mg/dl)
- Cardiovascular and respiratory failure
- Obstructive jaundice (bilirubin level >3.0 mg/dl)
- Renal failure (serum creatinine >2 mg%)
- Ascites
- Florid infection
- Partial or complete thrombosis of portal vein
- Contraindication for angiography

Imaging technique

To document the tumor size and tumor location before the treatment, unenhanced and contrast-enhanced [application of 0.1 mmol of gadopentate dimeglumine (Magnevist, Schering, Berlin, Germany) per kilogram body weight] T1-weighted gradient-echo sequences (FLASH-2D) with transversal and sagittal slice orientation (TR/TE: 135/6 ms; FA 80°; FOV 350 mm; matrix 134×256; slice thickness 8 mm). MRI studies were carried out for all patients with a conventional 1.5-T system (Magnetom Symphony; Siemens, Erlangen, Germany).

Additional non-enhanced T2-weighted turbo-spin-echo (TSE) sequences (TR/TE: 3,800/92 ms; FA 150°; FOV 350 mm; matrix 115×256; slice thickness 8 mm) and contrast-enhanced dynamic VIBE sequences (TR/TE: 4.5/1.8 ms; FA 15°; FOV 350 mm; matrix 128×256; slice thickness 8 mm) were used for the differentiation of the lesions.

Lipiodol retention in the tumor and the liver parenchyma was verified with nonenhanced CT examinations using the spiral technique (slice thickness, 8 mm) 24 h after TACE on fourth-generation scanners (Somatom plus or Somatom plus 4, Siemens, Erlangen, Germany). In addition, extrahepatic uptake of chemoembolization material was eliminated on these images.

To evaluate the tumor size during the TACE treatments, non-enhanced MRI studies were performed after every TACE cycle using either a 1.5-T system (Magnetom Symphony, Siemens) with FLASH-2D sequences in transversal and sagittal slice orientation and T2-weighted TSE sequences or a 0.5-T (Privileg; Elscint, Haifa, Israel) MRI system with gradient-echo (GRE) sequences (TR/TE: 140/12 ms; FA 80°; FOV 350 mm; matrix 128×200; slice thickness 8 mm) and T1-weighted SE sequences (TR/TE:

450/14 ms; FA 180°; FOV 350 mm; matrix 180×256; slice thickness 8 mm). To simplify the clinical laps for the patients, we renounced the application of contrast medium after every TACE cycle. For that reason, we evaluated only the size of the liver tumors.

Tumor volume before and after TACE and necroses after MR-guided LITT were calculated with the ellipsoidal volume formula:

$$Volume = (length \times width \times height \times 0.523)$$

For volume measurement, we used the axial images to evaluate the longest cross-section diameter as the length and the perpendicular diameter as the width. The height was documented as the longest diameter in sagittal images.

For our neoadjuvant treatment protocol, a response to the TACE treatment was defined as achieving shrinkage of the target large lesions to a maximum diameter less than 50 mm after the third treatment course. Stable disease was defined as a non-significant change in size during the TACE treatment courses and progressive disease as an increase of 25% in the size of a target lesion during TACE or newly developing lesions in the liver.

TACE technique

All angiographies were performed with the digital subtraction angiography (DSA) technique at an Axiom Multistar system (Siemens; Erlangen). After the introduction of a 4–5 French sheath into a femoral artery, an angiographic survey of the abdominal vessels was performed using a 4–5 French pigtail catheter in the first TACE course. After exclusion of the presence of a right hepatic artery by selective catheterization of the mesenteric artery, indirect portography followed, outlining the portal circulation in the venous phase. Afterwards, a 4–5 French Cobra catheter (Terumo, Frankfurt/Main, Germany) was placed in the coeliac trunk and advanced beyond the gastroduodenal artery. If possible, the tip of the catheter was advanced further into segmental arteries adjacent to the tumor.

The embolization suspension, containing a maximum of 10 mg/m² mitomycin C (Medac, Hamburg, Germany) as a chemotherapeutic agent and a maximum of 15 ml Lipiodol, an iodized oil (Guerbet, Sulzbach, Germany), followed by the injection of 200–450 mg microspheres (Sperex, Pharmacia & Upjohn, Erlangen) for vascular occlusion, was applied slowly under fluoroscopic control.

Devascularization after embolization was confirmed by an additional angiographic study of the hepatic artery. Transarterial chemoembolization was performed three times with a treatment interval of 4 weeks, because several reports have described better response rates for repeated TACE procedures in comparison to a single administration

[15, 21]. If the treated lesions showed no response after the third treatment, or the lesions were still larger than 50 mm in diameter, we continued the TACE treatment.

Laser technique

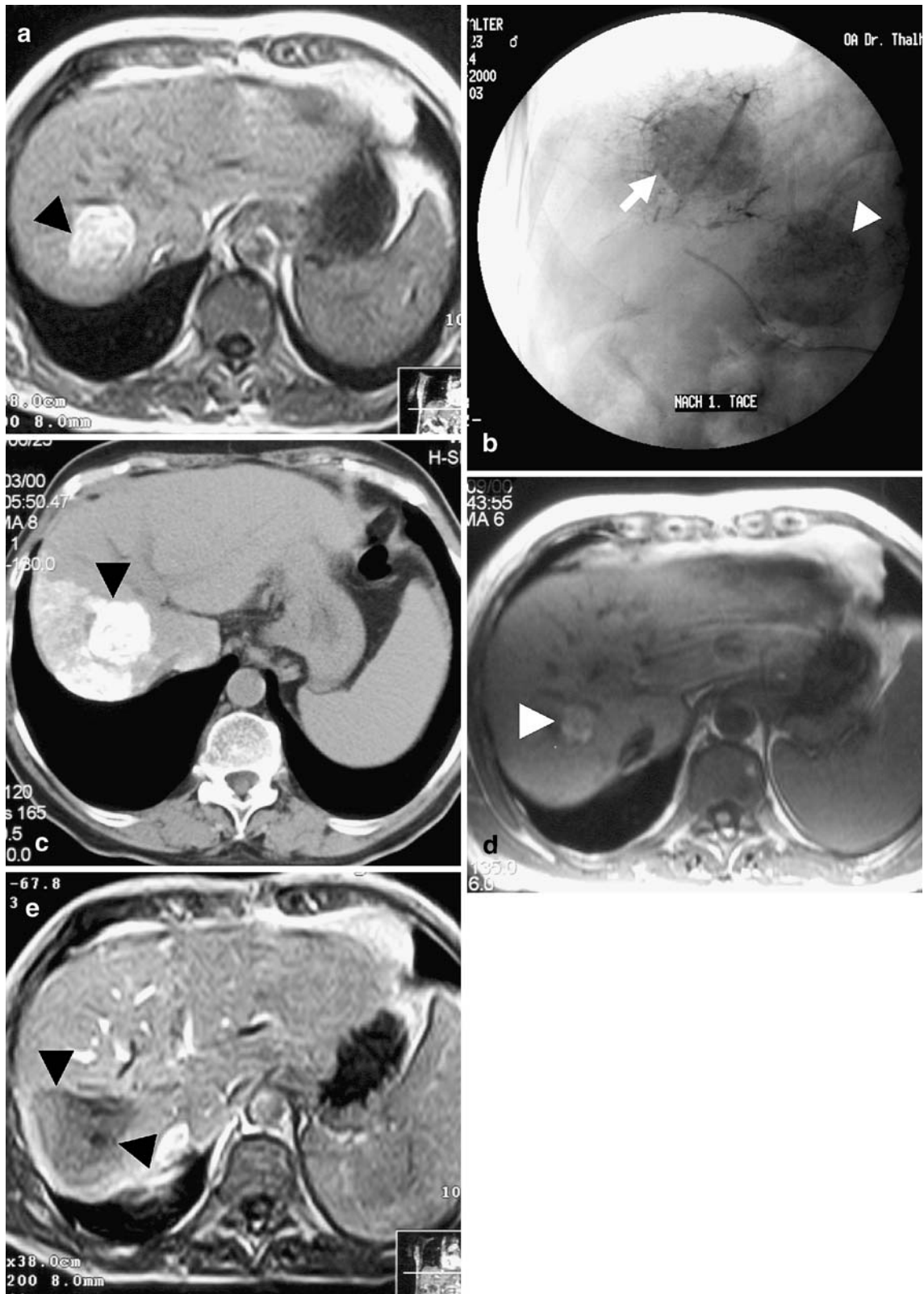
After proven size reduction of the large hepatic lesions to a diameter less than 50 mm in the MR images after TACE, the patients underwent MRI-guided LITT 4 to 6 weeks after the final TACE course. This treatment gap was necessary to guarantee a good condition of the patients before the laser ablation.

Introduction of the laser application set was performed with CT guidance under local anesthesia. Afterwards, the patients were transported with a stretcher to the MRI unit. The laser application kit (Somatex, Berlin) consists of a cannulation needle with a tetragonally sharpened tip and guide wire, a sheath system with a mandrin (length 20 cm; 10 French) and a special protective catheter (length 43 cm; 9 French), which is closed at the distal end. The protective catheter prevents direct contact of the laser applicator with the patient and allows complete removal of the applicator. This increases safety and simplifies the procedure. The catheter is light transparent and heat resistant (<400°C). The LITT system is permanently cooled with water to prevent carbonization of the tip during the laser treatment, resulting in a decreased volume of coagulation necrosis. A neodymium yttrium-aluminum-garnet (Nd:YAG) laser (Dornier MedLas 5060 and 5100) was used for the generation of light of near-infrared (1,046 nm) wavelength for the interstitial thermal ablation of the tumor. The laser energy was delivered to the tumor with fibers 10 m in length. Necrosis up to 2.5 cm can be created with a single laser applicator. For that reason, the multiple-application technique was used for the large lesions. Additionally, thermally induced changes by laser energy were adapted to the geometric features of the given lesion with the use of the pull-back technique, as described before [7].

Temperature development during the laser treatment was monitored by a thermosensitive T1-weighted FLASH-2D sequence (TR/TE: 140/12 ms; FA 80°; FOV 350 mm; matrix 128×200; slice thickness 8 mm; acquisition time 15 s).

After the LITT treatment, Gd-DTPA (Schering, Germany; 0.1 mmol/kg b.w.) was applied, and the laser-induced necrosis and possible complications were documented with FLASH-2D sequences (TR/TE: 140/12 ms; FA 80°; FOV 350 mm; matrix 128×200 slice thickness 8 mm).

Twenty-four hours after the LITT treatment, the size of the induced necrosis was documented with unenhanced and contrast-enhanced [application of 0.1 mmol of gadopentate dimeglumine (Magnevist, Schering, Berli) per kilogram b.w.] T1-weighted gradient-echo sequences (FLASH-2D) with transversal and sagittal slice orientation (TR/TE: 135/6 ms; FA 80°; FOV 350 mm; matrix 134×256; slice thickness 8 mm). Additional non-enhanced



T2-weighted turbo-spin-echo (TSE) sequences (TR/TE: 3,800/92 ms; FA 150°; FOV 350 mm; matrix 115×256;

slice thickness 8 mm) and contrast-enhanced dynamic VIBE sequences (TR/TE: 4.5/1.8 ms; FA 15°; FOV

◀ **Fig. 1** A 62-year-old patient with two HCC nodules larger than 5 cm. (a) Transverse GRE T1-weighted (TR/TE=135/6; flip angle 80°) MR image showed a HCC nodule (*arrow*) in segment 7. The coronal orientation presented a lesion with a diameter of 55 mm. (b) Frontal angiogram during the first course of chemoembolization revealed the good Lipiodol pexis of the target liver tumors (*arrow*) and an additional target lesion (not shown in (a) (*arrowhead*)). (c) Unenhanced transverse CT scan also documented a high Lipiodol retention (*arrow*) 24 h after the first TACE course. (d) Unenhanced transverse GRE MR image (TR/TE=140/12; flip angle 80°) obtained after the third course of TACE with a 70% decrease in tumor volume (*arrows*), so that MR-guided LITT could be performed after 6 weeks. (e) Contrast-enhanced transverse MR scan (TR/TE=135/6; flip angle 80°) 24 h after LITT demonstrated the ablated volume (*arrowheads*) without contrast enhancement in the coagulation area

350 mm; matrix 128×256; slice thickness 8 mm) were used.

All successfully ablated lesions appear as areas without contrast enhancements at follow-up MRI. All peripheral enhanced lesions at short-term follow-up within 1 month after treatment were not regarded as a residual viable tumor. However, remaining contrast enhancement in the area of the treated tumor was assessed as an incomplete ablation.

Follow-up examinations were obtained always after 3 months with contrast-enhanced MRI using the previously described imaging parameters. The cumulative survival time was calculated from the beginning of the first TACE treatment using the Kaplan-Meier method [22].

Results

Preprocedural findings

Pre-interventional MRI or CT studies of the liver were documented in 48 patients with unresectable HCCs who were treated with neoadjuvant intention. In these patients, an average of 1.6 lesions with a maximum diameter of

50 mm or greater could be observed. All patients were in good physical condition and were classified in a Child A stage.

Intraprocedural findings and short-term results after TACE

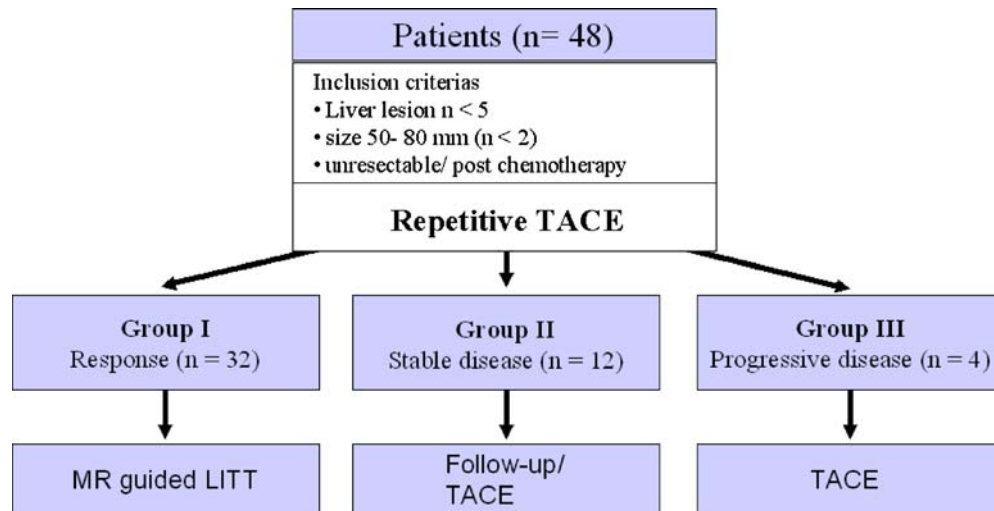
In all neoadjuvantly treated patients, 195 TACE procedures were performed in the absence of contraindications to the procedure with an average of 3.5 TACE procedures per patient. Technically, all TACE treatments were performed successfully. During and directly after TACE, no major complications were observed.

The MRI scans after the final course of TACE demonstrated in 32 patients (66.7%) of the neoadjuvant group (7 females and 25 males) a decreased size of the treated lesions, so that MR-guided LITT could follow after 4 to 6 weeks (Fig. 1). For the other patients, stable disease after the third course of TACE could be observed in 12 (25.0%) and progressive disease in 4 (8.3%) patients (Fig. 2).

Outcome after LITT and follow-up

In the response group, 69 LITT treatments (mean: 1.9 LITT procedures per patient) were performed after the TACE courses, resulting in a safe ablation of the treated liver tumors. Based on the size and topographical relationship of the tumors, a minimum number of two applicator systems and a maximum number of five applicator systems were positioned with a mean of 3.2 applicator systems per MR-guided LITT. In all lesions that were treated with MR-guided LITT, a complete ablation was observed 24-h after LITT contrast-enhanced MR images. During the 6-month follow-up, local recidivism could be observed in two patients (6.3%) who were treated again with TACE. In the further follow-up, newly developed lesions were

Fig. 2 Flow chart of the neoadjuvant study



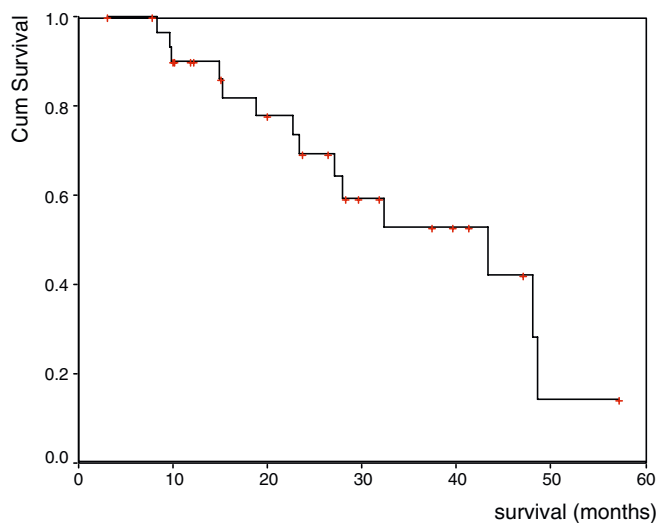


Fig. 3 Survival data of the patients treated with the neoadjuvant treatment protocol ($n=32$) calculated by the Kaplan-Meier method. The mean survival of the patients was 36.0 months (95% confidence interval 29.3–42.6)

observed in two patients who were treated with TACE again. During our observation time, 14 patients died. Causes of death were tumor progression in five patients, hepatic failure in three patients and other reasons in six patients. Based on these data, the cumulative survival time of the patients treated with the combined protocol was 36.0 months (95% confidence interval 29.3–42.6) after the first treatment (Fig. 3).

Complications

Generally, the patients tolerated the TACE procedure well. No fatal or major complications related to this step of treatment were observed.

In 88.2% of the patients, the side effects observed after TACE were mild (no or few symptoms). They included fever, abdominal pain, nausea and vomiting for 2–7 days and could be treated with oral medication (metamizol; metoclopramid). All patients were discharged on the same day after TACE treatment. There was no procedure-related mortality. During and immediately after laser treatments, no major complications occurred. In 15 patients (31.25%), minor complications such as pain, pleural effusion or subcapsular hematoma were noted after the LITT treatments, which did not have to be treated. Follow-up did not show any long-term sequelae or worsening of the liver function in any patients after the combined protocol.

Discussion

Surgery is a therapeutic option in only 15% of HCC cases because of the large size or multiplicity of the primary

tumors or accompanying cirrhosis. In general, 5-year survival rates of 25–40% are reported after surgery [23]. Mok et al. also showed that the advantage of hepatic resection in patients with large HCC is only marginal [24].

Several other minimally invasive treatment modalities have been developed for the treatment of liver tumors, including laser-induced thermotherapy (LITT), radiofrequency ablation (RF), microwave ablation, cryotherapy or percutaneous ethanol injection (PEI). These techniques for the percutaneous destruction of hepatic tumors are increasing in importance as an alternative treatment option for surgical treatment [7, 12, 14, 25–29]. A few studies have reported that these procedures are virtually free of significant side effects [7, 25, 30].

Currently, all methods of local ablation are limited by the size of the coagulation areas. Curley and Izzo suggested that RFA is a safe, well-tolerated, effective treatment for unresectable hepatic malignancies less than 6.0 cm in diameter [31]. Improved overall results after MR-guided LITT were obtained with the use of liquid-cooled applicator systems and improved application techniques, resulting in areas of coagulation necrosis up to 6–8 cm. However, for the reduction of a tumor relapse, a safety margin of 1 cm is imperative. From this, it follows that a treatment of tumors with a maximum diameter of 4–6 cm is quite possible [32]. Additional hepatic perfusion is a major factor limiting the size of the coagulation areas produced by laser ablation. Several previous studies have shown a reduced size of coagulation areas by hepatic inflow [30, 33] and preservation of viable cells surrounding larger vessels after laser ablation. These cells probably survive as a result of the cooling effect provided by the blood flow and increase the risk of tumor recurrence [34, 35].

For these reasons, TACE is the most widely used treatment for unresectable HCC in many countries [3, 4, 13]. Meta-analyses of data from multiple trials have shown that chemoembolization improves the survival of patients with unresectable HCC and may become the standard treatment [36, 37]. In an animal study, it could be demonstrated that the combination of TACE with immune and antiangiogenesis therapy results in reduced tumor growth compared with TACE alone [38]. This might be a possible therapeutic option in the future. Nevertheless, these results must be evaluated for the treatment of HCC in clinical studies.

The embolization of the hepatic artery during TACE reduces the blood flow, creates ischemia and increases the contact time between the chemotherapeutic agent and the tumor cells, resulting in an increased local effect on the neoplasm with only slight damage to the surrounding liver tissue [39]. Nevertheless, viable tumor cells may remain after TACE treatment [20]. Thus, the antitumor effect of TACE has been substantiated in RCTs with a mean partial response rate of 26.9%, while the mean complete response rate was only 6% [36]. TACE alone has resulted in long-term survival for patients with

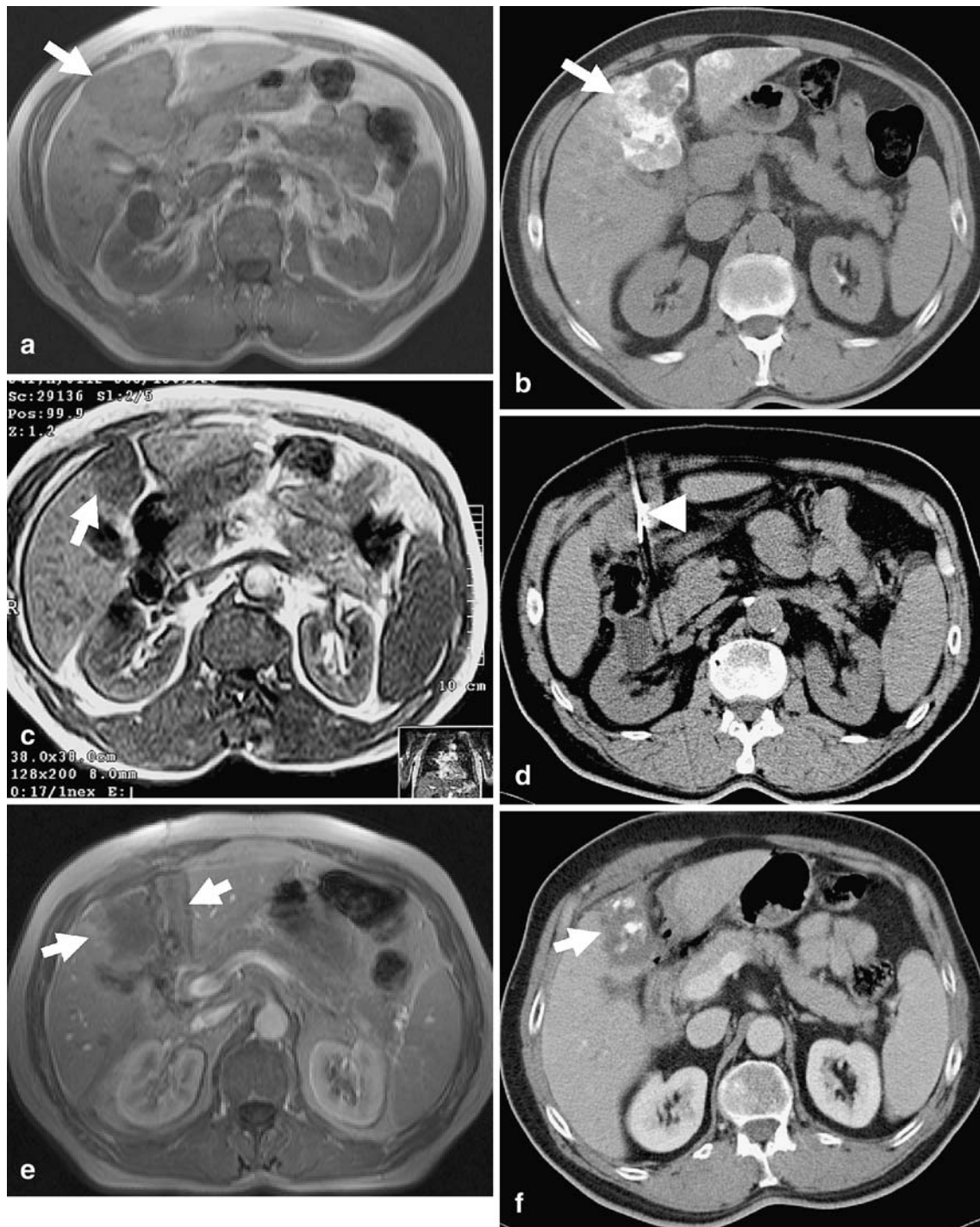


Fig. 4 A 64-year-old patient with a large HCC nodule in segment 4 and three further lesions. (a). Documentation of the largest lesion (*arrow*) in transverse GRE T1-weighted (TR/TE=140/12; flip angle 80°) MR images. (b) Unenhanced transverse CT scan after the second course of chemoembolization also documented high lipiodol retention (*arrow*) in the treated tumor and a beginning of tumor decrease. (c) After the third course of TACE, a 60% decrease of the tumor (*arrow*) could be observed on unenhanced transverse GRE

MR images (TR/TE=135/6; flip angle 80°). (d) Unenhanced transverse CT scan obtained during the application of the laser catheters (*arrowhead*). (e) Contrast-enhanced transverse MR scan (TR/TE=140/12; flip angle 80°) 24 h after LITT demonstrated the ablated volume (*arrows*), characterized by a low signal intensity surrounded by a hyperintense rim. (f) Contrast-enhanced transverse CT scan 4 weeks after the LITT documented the coagulation area (*arrow*) with Lipiodol remnant of the TACE in the treated tumor

HCC, especially for patients who either have low serum alpha-fetoprotein values (<1,500 ng/dl) or a relatively small nodular tumor with a maximum tumor diameter <5.5 cm and the absence of portal vein involvement [40]. However, the TACE treatment of patients with large hepatocellular carcinoma (HCC) is particularly difficult [15]. Patients with tumors greater than 5 cm have a higher prevalence of extracapsular tumor invasion into the liver parenchyma, more frequent intrahepatic dissemination by way of the portal vein branches and worse survival rates than those with smaller tumors [24]. For these reasons, the control of large nonnodular lesions with TACE only is still a challenging problem [41].

Thus, new treatment options for large HCC aimed at decreasing the risk of recurrence and improving survival are needed, such as the combination of TACE with local ablative techniques for the treatment of large malignant hepatic tumors.

Various reports with promising results after combined treatment protocols have been published. Patients with inoperable HCCs treated with the combination of TACE and PEI have a better survival rate than patients treated only with repeated TACE [14, 42, 43]. However, Lencioni et al. showed that the use of local thermal ablation techniques such as radiofrequency (RF) results in superior local recurrence-free survival rates in comparison to percutaneous ethanol injection (PEI) for the treatment of small hepatocellular carcinoma (HCC) in patients with cirrhosis [28]. Likewise, TACE combined with other local ablative treatment options such as MR-guided LITT or radiofrequency (RF) ablation increases the effectiveness of the treatment, and better results were observed with the combined protocol than with either of these therapies alone [32, 43–46]. Consequently, experimental studies also found that temporary interruption of blood flow to the liver significantly increased the coagulated area during the laser treatment [33, 47, 48]. In these cases, laser coagulation for treating liver tumors should preferably be performed by application routes that permit temporary interruption of hepatic perfusion [47]. Likewise, temporary hepatic vein or portal branch occlusion during radiofrequency ablation could safely facilitate the treatment of large tumors or tumors in contact with the walls of large vessels [49].

Yamakado et al. achieved complete necrosis in all lesions regardless of the tumor size or morphology after the combination of RF ablation within 2 weeks after single chemoembolization [50]. These studies also showed a limitation of the therapeutic effect of this combined therapy strategy. One third of large non-nodular lesions recurred beyond tumor-free margins. Pacella et al. showed that laser thermal ablation followed by TACE is an effective palliative therapy in treating large HCCs [51]. However, on imaging after LITT, a necrosis that was more than 50% of the tumor was documented in 60% of the large tumors, so that they performed TACE for the treatment of the viable

residual tumor cells. After combined treatment, complete response was then achieved in 90%. The rationale for combining these techniques was based on the fact that LITT reduces the volume of viable tissue and brings the lesion size back within the range of TACE effectiveness [51].

However, in our opinion, only complete thermal ablation of the liver tumors results in satisfying results, which are only possible if the lesions are smaller than 5 cm in diameter. For that reason, the rationale of our study was to perform TACE to decrease the tumor size of previously unresectable large-sized liver tumors, thus allowing the destruction of focal tumors using minimally invasive percutaneous ablative treatments like MR-guided LITT.

With our study, we could show that neoadjuvant TACE decreased the tumor size in two-thirds of the treated patients, forming the basis for complete laser ablation of all treated HCCs with blood inflow occlusion of the hepatic tumors by TACE (Fig. 4). The published treatment intervals between TACE cycles range from 4 to 12 weeks [20, 52, 53]. Due to our experiences with TACE and LITT, we chose a 4-week interval between TACE treatments. Fan et al. described a median interval of 2.5 months between the last TACE and subsequent liver resection [20]. Because LITT is less invasiveness in comparison to surgical treatments, we performed LITT 4 to 6 weeks after the final TACE course.

No significant side effects were observed in our patient group, so the treatments could be performed in an outpatient setting. Our results also showed that neoadjuvant TACE before local ablative treatments results in satisfactory survival rates with a mean survival of 36.0 months.

Different survival rates after TACE were published ranging between 7.9 and 17.3 months depending on the tumor type, tumor size and grade of liver cirrhosis [15, 54]. The median survival rate of patients with HCC tumors smaller than 5 cm in diameter was 32 months after the sole treatment with LITT [55]. In comparison to these results, the survival rates of the neoadjuvant-treated patients were distinctly higher in comparison to the single treatment with TACE and comparable to the results of single treatment with LITT. However, these promising results have to be confirmed with a randomized study to compare the combined protocol with single TACE and LITT treatment. Similar results were described for RF thermal ablation performed after TACE in patients with HCCs [56, 57].

Nevertheless, this study has some limitation. To reduce the stress for the patients after TACE, we did the MRI examinations without the application of contrast. While the size of the tumor could be evaluated easily, we could not differentiate between necrosis and viable tumor after the treatment. However, the performed CT examination with documentation of the Lipiodol uptake in the tumor could provide additional information on the degree of tumor necrosis [58, 59].

For further evaluation of the therapeutic effects after TACE of hepatocellular carcinoma, different imaging modalities are available, such as contrast-enhanced CT or MRI, sonography, proton MR spectroscopy and sonography [59–63].

Kubota et al. published a sensitivity, specificity and accuracy for Lipiodol CT of 76.0, 67.6 and 72.6% and for PD sonography of 34.0, 100 and 60.7%. Dynamic MRI achieved 100% sensitivity, 100% specificity and 100% accuracy [63].

While a response to the neoadjuvant TACE was documented in two-thirds of the patients, this experimental design does not distinguish between the effects of chemoembolization and the effects of LITT. The long-term survival rates were not evaluated in this study. A further problem is the small number of our patient group.

While data about the cost-effectiveness of TACE in patients with colorectal liver metastases have been published, no publications about the cost-effectiveness of TACE in HCC-patients are available [64]. The combined

treatment with TACE and LITT increases the cost of the treatment. We did not evaluate the cost-effectiveness of this combined treatment protocol in this study. This is an important question that needs to be evaluated in the future. For these reasons, randomized studies are necessary to evaluate different prognostic factors of the neoadjuvant treatment protocol, including correlation with long-term clinical follow-up and treatment costs.

Conclusion

Repeated TACE treatment appears to be an effective and safe treatment of initially large-sized unresectable HCCs with the additional neoadjuvant potential intention. Neoadjuvant TACE extended the indication for thermal ablative techniques, such as MR-guided LITT, which should be performed when the tumor has shrunk after TACE in order to increase the survival rates.

References

1. Bruix J, Sala M, Llovet J (2004) Chemoembolization for hepatocellular carcinoma. *Gastroenterology* 127: S179–S188
2. Taylor-Robinson SD, Foster GR, Arora S, Hargreaves S, Thomas HC (1997) Increase in primary liver cancer in the UK, 1979–94. *Lancet* 350:1142–1143
3. Llovet J, Sala M (2005) Non-surgical therapies of hepatocellular carcinoma (In Process Citation). *Eur J Gastroenterol Hepatol* 17:505–513
4. Bruix J, Sherman M, Llovet J et al (2001) Clinical management of hepatocellular carcinoma. Conclusions of the Barcelona-2000 EASL Conference. European Association for the Study of the Liver. *J Hepatol* 35:421–430
5. Livraghi T, Giorgio A, Marin G et al (1995) Hepatocellular carcinoma and cirrhosis in 746 patients: long-term results of percutaneous ethanol injection. *Radiology* 197:101–108
6. Ishii H, Okada S, Nose H et al (1996) Local recurrence of hepatocellular carcinoma after percutaneous ethanol injection. *Cancer* 77:1792–1796
7. Vogl TJ, Straub R, Eichler K, Woitaschek D, Mack MG (2002) Malignant liver tumors treated with MR imaging-guided laser-induced thermotherapy: experience with complications in 899 patients (2,520 lesions). *Radiology* 225:367–377
8. Nikfarjam M, Christophi C (2003) Interstitial laser thermotherapy for liver tumours. *Br J Surg* 90:1033–1047
9. Midorikawa T, Kumada K, Kikuchi H et al (2000) Microwave coagulation therapy for hepatocellular carcinoma. *J Hepatobiliary Pancreat Surg* 7:252–259
10. Ishida T, Murakami T, Shibata T, Inoue Y, Takamura M, Niinobu T, Sato T, Nakamura H (2002) Percutaneous microwave tumor coagulation for hepatocellular carcinomas with interruption of segmental hepatic blood flow. *J Vasc Interv Radiol* 13:185–191
11. Allgaier HP, Deibert P, Zuber I, Olschewski M, Blum HE (1999) Percutaneous radiofrequency interstitial thermal ablation of small hepatocellular carcinoma. *Lancet* 353:1676–1677
12. Livraghi T (2003) Radiofrequency ablation, PEIT, and TACE for hepatocellular carcinoma. *J Hepatobiliary Pancreat Surg* 10:67–76
13. Llovet J, Burroughs A, Bruix J (2003) Hepatocellular carcinoma. *Lancet* 362:1907–1917
14. Allgaier HP, Deibert P, Olschewski M, Spamer C, Blum U, Gerok W, Blum HE (1998) Survival benefit of patients with inoperable hepatocellular carcinoma treated by a combination of transarterial chemoembolization and percutaneous ethanol injection—a single-center analysis including 132 patients. *Int J Cancer* 79:601–605
15. Vogl TJ, Trapp M, Schroeder H, Mack M, Schuster A, Schmitt J, Neuhaus P, Felix R (2000) Transarterial chemoembolization for hepatocellular carcinoma: volumetric and morphologic CT criteria for assessment of prognosis and therapeutic success—results from a liver transplantation center. *Radiology* 214:349–357
16. Lee K, Sung K, Lee D, Park S, Kim K, Yu J (2002) Transcatheter arterial chemoembolization for hepatocellular carcinoma: anatomic and hemodynamic considerations in the hepatic artery and portal vein. *Radiographics* 22:1077–1091
17. Mondazzi L, Bottelli R, Brambilla G, Rampoldi A, Rezakovic I, Zavaglia C, Alberti A, Ideo G (1994) Transarterial oily chemoembolization for the treatment of hepatocellular carcinoma: a multivariate analysis of prognostic factors. *Hepatology* 19:1115–1123
18. O’Suilleabhain CB, Poon RT, Yong JL, Ooi GC, Tso WK, Fan ST (2003) Factors predictive of 5-year survival after transarterial chemoembolization for inoperable hepatocellular carcinoma. *Br J Surg* 90:325–331
19. Okazaki M, Yamasaki S, Ono H et al (1993) Chemoembolotherapy for recurrent hepatocellular carcinoma in the residual liver after hepatectomy. *Hepatogastroenterology* 40:320–323

20. Fan J, Tang ZY, Yu YQ, Wu ZQ, Ma ZC, Zhou XD, Zhou J, Qiu SJ, Lu JZ (1998) Improved survival with resection after transcatheter arterial chemoembolization (TACE) for unresectable hepatocellular carcinoma. *Dig Surg* 15:674–678
21. Tellez C, Benson AB, 3rd, Lyster MT, Talamonti M, Shaw J, Braun MA, Nemcek AA Jr, Vogelzang RL (1998) Phase II trial of chemoembolization for the treatment of metastatic colorectal carcinoma to the liver and review of the literature. *Cancer* 82:1250–1259
22. Kaplan EL, Meier P (1958) Nonparametric estimation from incomplete observation. *J Am Stat Assoc* 53:457–481
23. Nagasue N, Kohno H, Chang YC et al (1993) Liver resection for hepatocellular carcinoma. Results of 229 consecutive patients during 11 years. *Ann Surg* 217:375–384
24. Mok KT, Wang BW, Lo GH et al (2003) Multimodality management of hepatocellular carcinoma larger than 10 cm. *J Am Coll Surg* 197:730–738
25. Curley SA, Izzo F, Ellis LM, Nicolas Vauthey J, Vallone P (2000) Radiofrequency ablation of hepatocellular cancer in 110 patients with cirrhosis. *Ann Surg* 232:381–391
26. Dwerryhouse SJ, Seifert JK, McCall JL, Iqbal J, Ross WB, Morris DL (1998) Hepatic resection with cryotherapy to involved or inadequate resection margin (edge freeze) for metastases from colorectal cancer. *Br J Surg* 85:185–187
27. Finlay IG, Seifert JK, Stewart GJ, Morris DL (2000) Resection with cryotherapy of colorectal hepatic metastases has the same survival as hepatic resection alone. *Eur J Surg Oncol* 26:199–202
28. Lencioni RA, Allgaier HP, Cioni D et al (2003) Small hepatocellular carcinoma in cirrhosis: randomized comparison of radio-frequency thermal ablation versus percutaneous ethanol injection. *Radiology* 228:235–240
29. Goldberg SN, Gazelle GS, Compton CC, Mueller PR, Tanabe KK (2000) Treatment of intrahepatic malignancy with radiofrequency ablation: radiologic-pathologic correlation. *Cancer* 88:2452–2463
30. Verhoef C, Kuiper JW, Heisterkamp J, de Man RA, Pattynama PM, JN IJ (2003) Interstitial laser coagulation with temporary hepatic artery occlusion for patients with cirrhosis and irresectable hepatoma. *Br J Surg* 90:950–955
31. Curley SA, Izzo F (2002) Radiofrequency ablation of hepatocellular carcinoma. *Minerva Chir* 57:165–176
32. Vogl TJ, Mack MG, Balzer JO, Engelmann K, Straub R, Eichler K, Woitaschek D, Zangos S (2003) Liver metastases: neoadjuvant downsizing with transarterial chemoembolization before laser-induced thermotherapy. *Radiology* 229:457–464
33. Wacker FK, Reither K, Ritz JP, Roggan A, Germer CT, Wolf KJ (2001) MR-guided interstitial laser-induced thermotherapy of hepatic metastasis combined with arterial blood flow reduction: technique and first clinical results in an open MR system. *J Magn Reson Imaging* 13:31–36
34. Whelan WM, Wyman DR, Wilson BC (1995) Investigations of large vessel cooling during interstitial laser heating. *Med Phys* 22:105–115
35. Matthewson K, Coleridge-Smith P, O'Sullivan JP, Northfield TC, Bown SG (1987) Biological effects of intrahepatic neodymium: yttrium-aluminum-garnet laser photocoagulation in rats. *Gastroenterology* 93:550–557
36. Camma C, Schepis F, Orlando A, Albanese M, Shahied L, Trevisani F, Andreone P, Craxi A, Cottone M (2002) Transarterial chemoembolization for unresectable hepatocellular carcinoma: meta-analysis of randomized controlled trials. *Radiology* 224:47–54
37. Llovet J, Bruix J (2003) Systematic review of randomized trials for unresectable hepatocellular carcinoma: Chemoembolization improves survival. *Hepatology* 37:429–442
38. Maataoui A, Qian J, Vossoughi D, Khan MF, Oppermann E, Bechstein WO, Vogl TJ (2005) Transarterial chemoembolization alone and in combination with other therapies: a comparative study in an animal HCC model. *Eur Radiol* 15:127–133
39. Tancredi T, McCuskey PA, Kan Z, Wallace S (1999) Changes in rat liver microcirculation after experimental hepatic arterial embolization: comparison of different embolic agents. *Radiology* 211:177–181
40. Yoshioka H, Sato M, Sonomura T, Terada M, Kishi K, Yoshikawa A (1997) Factors associated with survival exceeding 5 years after transcatheter arterial embolization for hepatocellular carcinoma. *Semin Oncol* 24:S6–29–S26–37
41. Yamakado K, Nakatsuka A, Ohmori S, Shiraki K, Nakano T, Ikoma J, Adachi Y, Takeda K (2002) Radiofrequency ablation combined with chemoembolization in hepatocellular carcinoma: treatment response based on tumor size and morphology. *J Vasc Interv Radiol* 13:1225–1232
42. Bartolozzi C, Lencioni R, Caramella D et al (1995) Treatment of large HCC: transcatheter arterial chemoembolization combined with percutaneous ethanol injection versus repeated transcatheter arterial chemoembolization. *Radiology* 197:812–818
43. Lencioni R, Paolicchi A, Moretti M et al (1998) Combined transcatheter arterial chemoembolization and percutaneous ethanol injection for the treatment of large hepatocellular carcinoma: local therapeutic effect and long-term survival rate. *Eur Radiol* 8:439–444
44. Rossi S, Garbagnati F, Lencioni R et al (2000) Percutaneous radio-frequency thermal ablation of nonresectable hepatocellular carcinoma after occlusion of tumor blood supply. *Radiology* 217:119–126
45. Takamura M, Murakami T, Shibata T et al (2001) Microwave coagulation therapy with interruption of hepatic blood in- or outflow: an experimental study. *J Vasc Interv Radiol* 12:619–622
46. Trevisani F, De Notariis S, Rossi C, Bernardi M (2001) Randomized control trials on chemoembolization for hepatocellular carcinoma: is there room for new studies? *J Clin Gastroenterol* 32:383–389
47. Albrecht D, Germer CT, Isbert C, Ritz JP, Roggan A, Muller G, Buhr HJ (1998) Interstitial laser coagulation: evaluation of the effect of normal liver blood perfusion and the application mode on lesion size. *Lasers Surg Med* 23:40–47
48. Heisterkamp J, van Hillegersberg R, Zondervan PE, JN IJ (1999) Long-term effects of interstitial laser coagulation in porcine liver with portal inflow occlusion: central versus peripheral lesions. *J Vasc Interv Radiol* 10:825–831
49. de Baere T, Bessoud B, Dromain C et al (2002) Percutaneous radiofrequency ablation of hepatic tumors during temporary venous occlusion. *AJR Am J Roentgenol* 178:53–59
50. Yamakado K, Nakatsuka A, Akeboshi M, Shiraki K, Nakano T, Takeda K (2004) Combination therapy with radiofrequency ablation and transcatheter chemoembolization for the treatment of hepatocellular carcinoma: Short-term recurrences and survival. *Oncol Rep* 11:105–109

-
51. Pacella CM, Bizzarri G, Cecconi P, Caspani B, Magnolfi F, Bianchini A, Anelli V, Pacella S, Rossi Z (2001) Hepatocellular carcinoma: longterm results of combined treatment with laser thermal ablation and transcatheter arterial chemoembolization. *Radiology* 219:669–678
 52. Kim HK, Chung YH, Song BC et al (2001) Ischemic bile duct injury as a serious complication after transarterial chemoembolization in patients with hepatocellular carcinoma. *J Clin Gastroenterol* 32:423–427
 53. Shah SR, Riordan SM, Karani J, Williams R (1998) Tumour ablation and hepatic decompensation rates in multi-agent chemoembolization of hepatocellular carcinoma. *Qjm* 91:821–828
 54. Huppert PE, Lauchart W, Duda SH, Torkler C, Kloska SP, Weinlich M, Benda N, Pereira P, Claussen CD (2004) Chemoembolization of hepatocellular carcinomas: which factors determine therapeutic response and survival? *Rofo* 176:375–385
 55. Vogl TJ, Mack M, Straub R, Eichler K, Engelmann K, Roggan A, Zangos S (2000) Percutaneous interstitial thermotherapy of malignant liver tumors. (Perkutane interstitielle Thermotherapie maligner Lebertumoren.). *Rofo Fortschr Geb Rontgenstr Neuen Bildgeb Verfahr* 172:12–22
 56. Bloomston M, Binitie O, Fraiji E et al (2002) Transcatheter arterial chemoembolization with or without radiofrequency ablation in the management of patients with advanced hepatic malignancy. *Am Surg* 68:827–831
 57. Buscarini L, Buscarini E, Di Stasi M, Quaretti P, Zangrandi A (1999) Percutaneous radiofrequency thermal ablation combined with transcatheter arterial embolization in the treatment of large hepatocellular carcinoma. *Ultraschall Med* 20:47–53
 58. Takayasu K, Arai S, Matsuo N et al (2000) Comparison of CT findings with resected specimens after chemoembolization with iodized oil for hepatocellular carcinoma. *AJR Am J Roentgenol.* 175:699–704
 59. Guan YS, Sun L, Zhou XP, Li X, Zheng XH (2004) Hepatocellular carcinoma treated with interventional procedures: CT and MRI follow-up. *World J Gastroenterol.* 10:3543–3548
 60. Chen CY, Li CW, Kuo YT, Jaw TS, Wu DK, Jao JC, Hsu JS, Liu GC (2006) Early response of hepatocellular carcinoma to transcatheter arterial chemoembolization: choline levels and MR diffusion constants—initial experience. *Radiology* 28:28
 61. Castrucci M, Sironi S, De Cobelli F, Salvioni M, Del Maschio A (1996) Plain and gadolinium-DTPA-enhanced MR imaging of hepatocellular carcinoma treated with transarterial chemoembolization. *Abdom Imaging* 21:488–494
 62. Kim HC, Kim AY, Han JK, Chung JW, Lee JY, Park JH, Choi BI (2002) Hepatic arterial and portal venous phase helical CT in patients treated with transcatheter arterial chemoembolization for hepatocellular carcinoma: added value of unenhanced images. *Radiology.* 225:773–780
 63. Kubota K, Hisa N, Nishikawa T, Fujiwara Y, Murata Y, Itoh S, Yoshida D, Yoshida S (2001) Evaluation of hepatocellular carcinoma after treatment with transcatheter arterial chemoembolization: comparison of Lipiodol-CT, power Doppler sonography, and dynamic MRI. *Abdom Imaging* 26:184–190
 64. Abramson R, Rosen M, Perry L, Brophy D, Raeburn S, Stuart K (2000) Cost-effectiveness of hepatic arterial chemoembolization for colorectal liver metastases refractory to systemic chemotherapy. *Radiology* 216:485–491