

Dental-CT: Untersuchungsstrategien und Pathologien: Was der Zahnarzt wissen will?

C. Krestan, C. Czerny, S. Plischke
Osteologie/Radiologie
AKH Wien MUW

Dental MDCT Indikationen

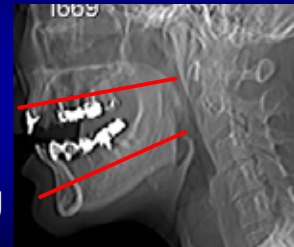
- Dysplasia (congenital)
- Ret. Zähne
- Entzündung
- Tumor
- Atrophie (Präimplantation)
- Posttherapie

Dental MDCT Technik

- Axial (parallel Ebene Ober-/Unterkiefer)
- Serial
- Thk 20x0,625mm, 16x0,75mm
- Rekon. 0,625mm, 0,8mm
- HR-Knochen Dental

Dental MDCT Technik

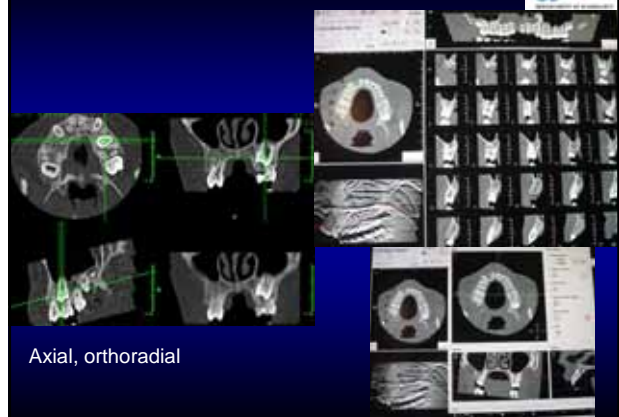
- Axial (parallel Ebene Ober-/Unterkiefer)
- Serial
- Gantry Neigung



Dental MDCT Technik


- Dokumentation Film/PACS
- Axiale Schichten
- Orthoradiale Rekonstruktionen
- „Orthopantomische“ Ansichten
- Film: 3 Filme

Dental MDCT Dokumentation



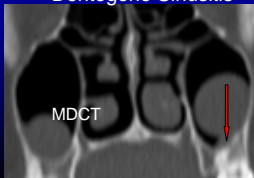
Dental MDCT Vorteile

- Keine Aufhängungsartefakte
- Dünnere Schichten
- Rekonstruktionen jede Ebene ohne „Stufenartefakte“
- **DLP OK 75,8 mGycm**
Kinder 32,6 mGycm bei 2cm Scanlänge



SCT


Dentogene Sinusitis




MDCT

Dental MDCT Vorteile

Keine Artefakte
Multiplanare Rekonstruktionen
Bessere Darstellung
Dosisadaptation Kinder



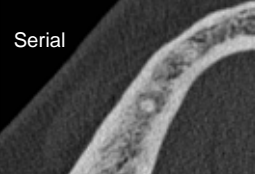
Mesiodens 21



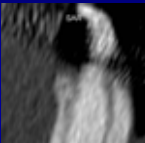
Dental MDCT Vorteile

Serial – Spirale


Unschärfe !!!



Serial




Serial




Spirale

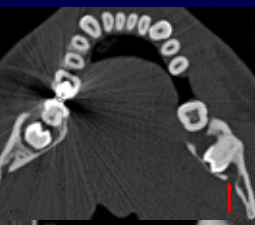
Congenital



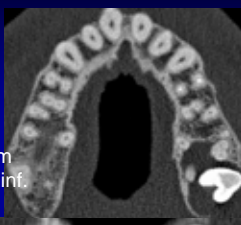
Ret. Zähne
Relation zu NNH




Congenital




Ret. Zähne
Relation zum
Nervus alv. inf.
und NNH

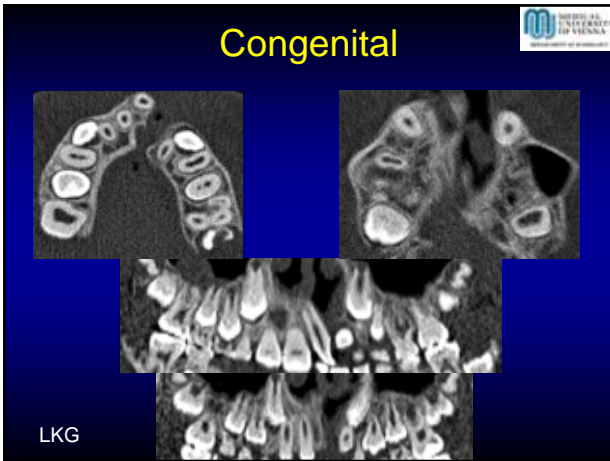


Congenital



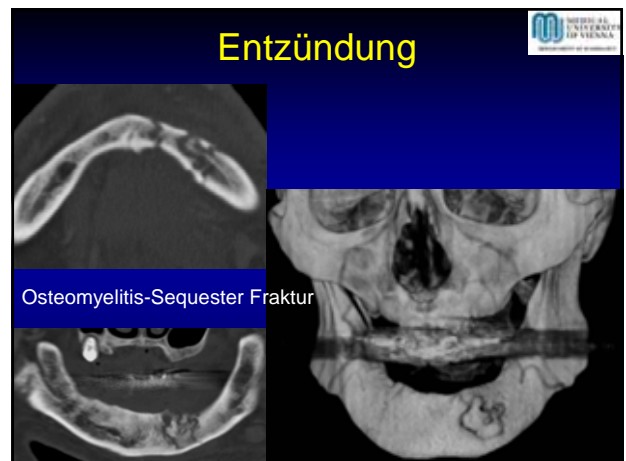
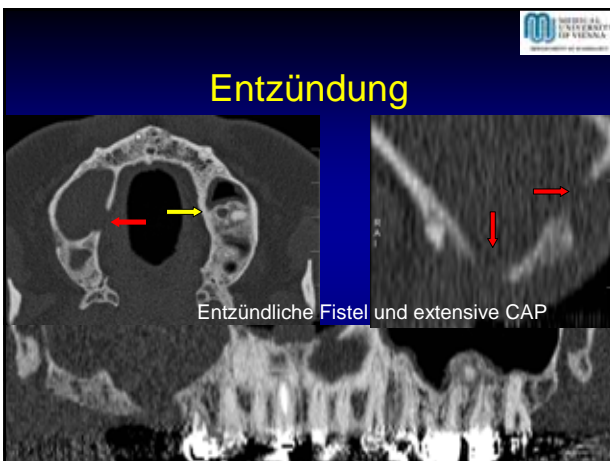
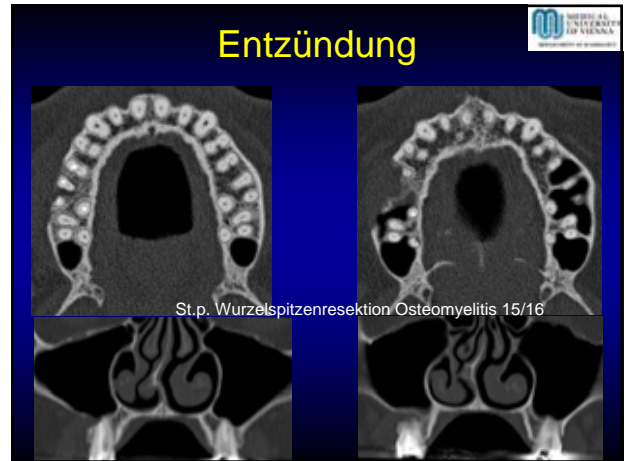
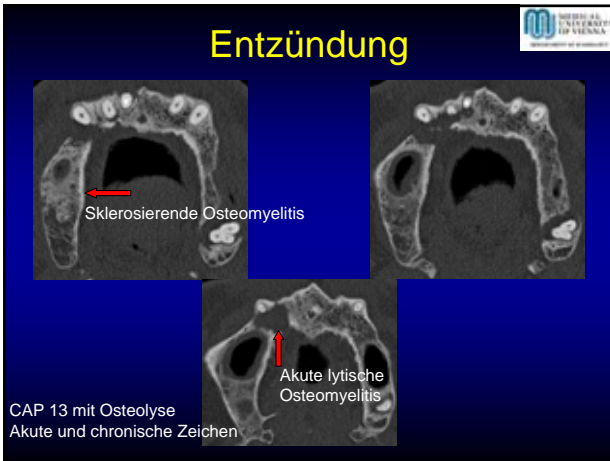
Hooked root 48

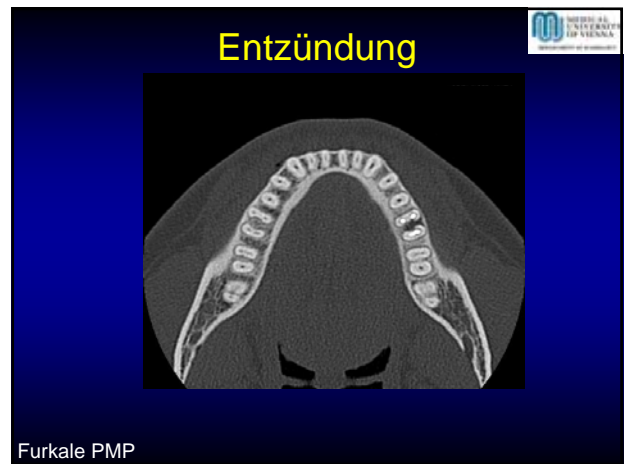
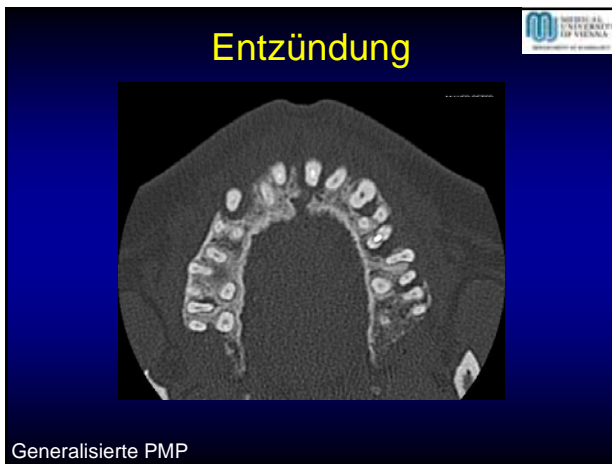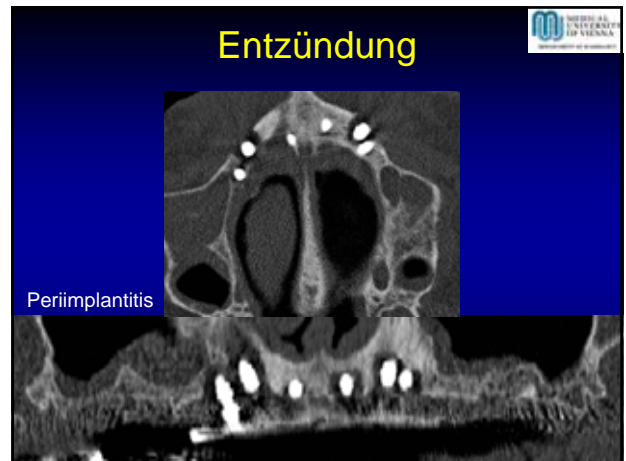
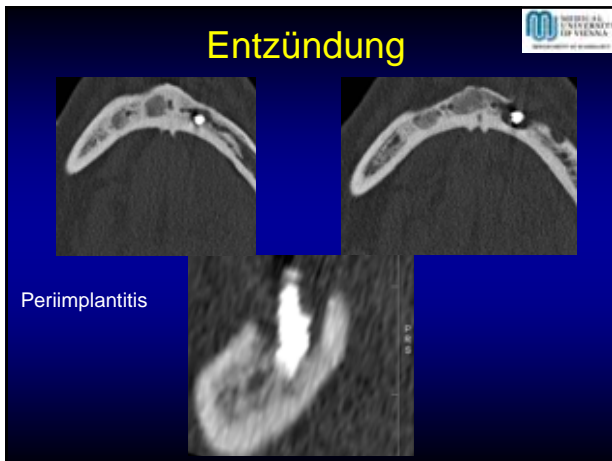




Entzündung/Tumor

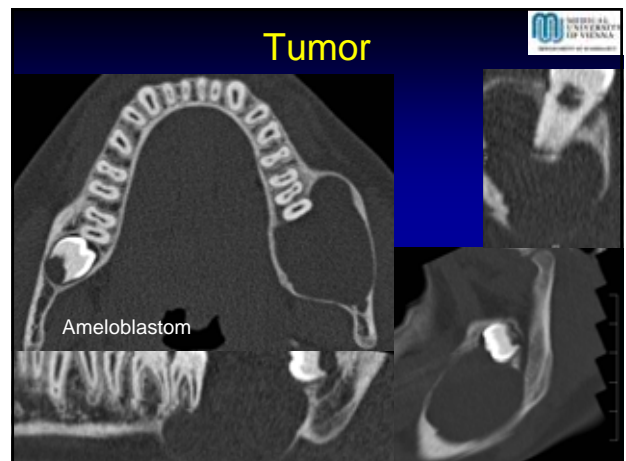
- Akute Osteomyelitis CT mglw. MR Abszess -/+?
- Chron. Osteomyelitis CT Sequester, Fraktur?
- DD Osteomyelitis-Tumor

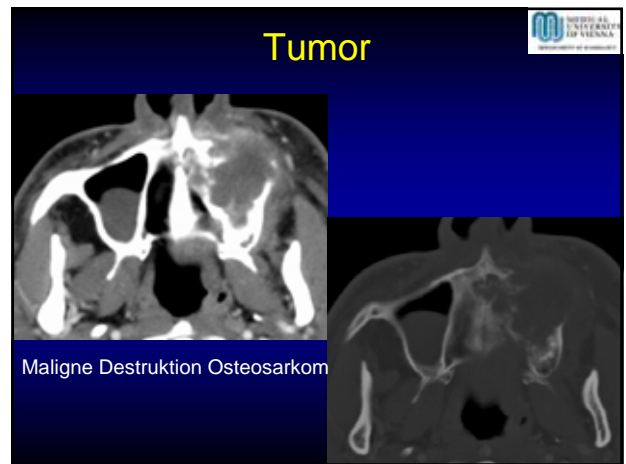
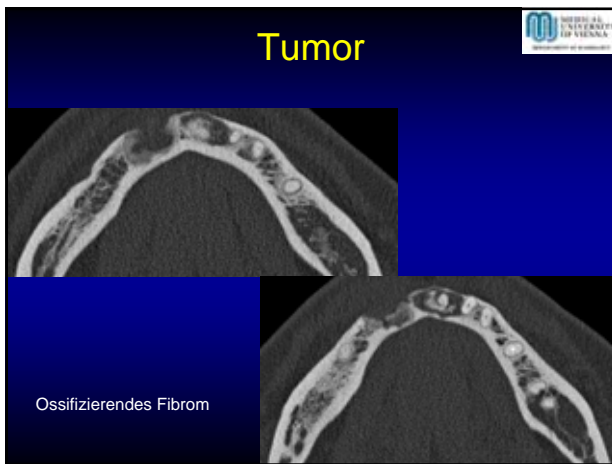
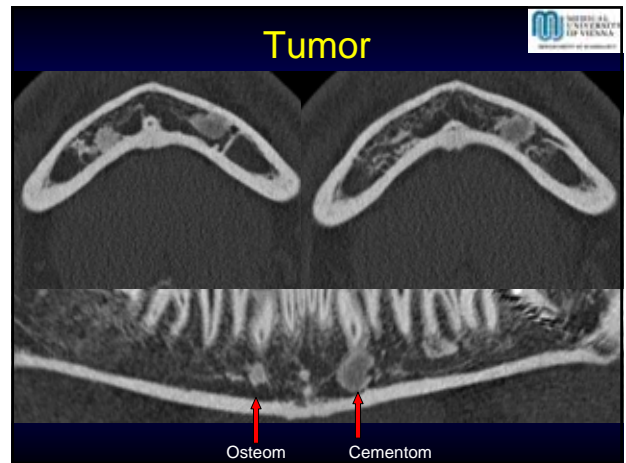
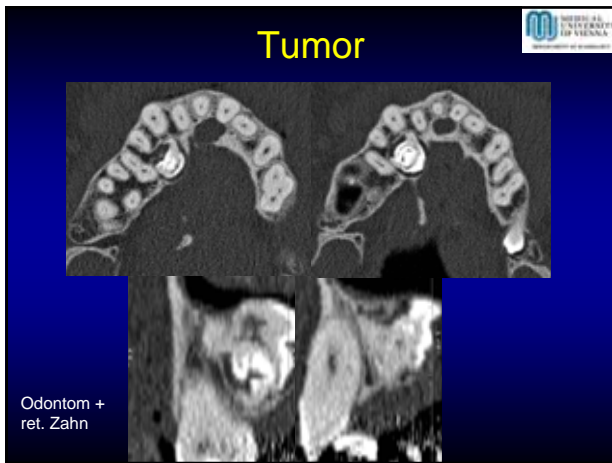




Tumor

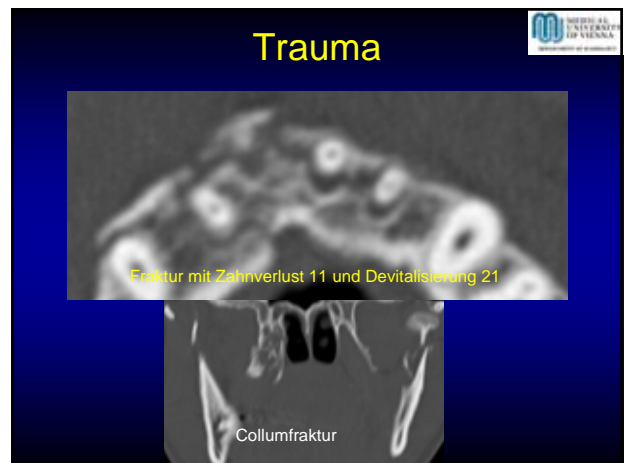
- Arrosion – Destruktion
- Benigne – Maligne
- Arrosion: Scharf, glatt, keine Periost-Kortikalisreaktion
- Destruktion: Irregulär, mottenfraß, periostale-kortikale Reaktion

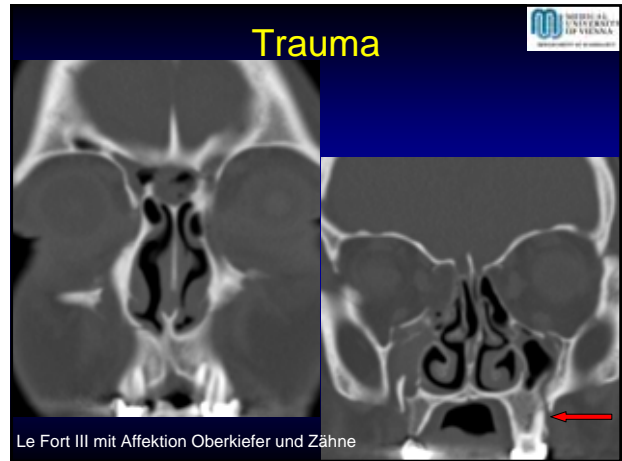
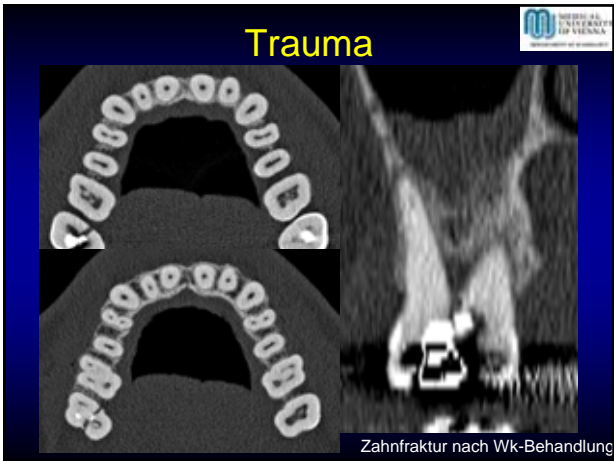




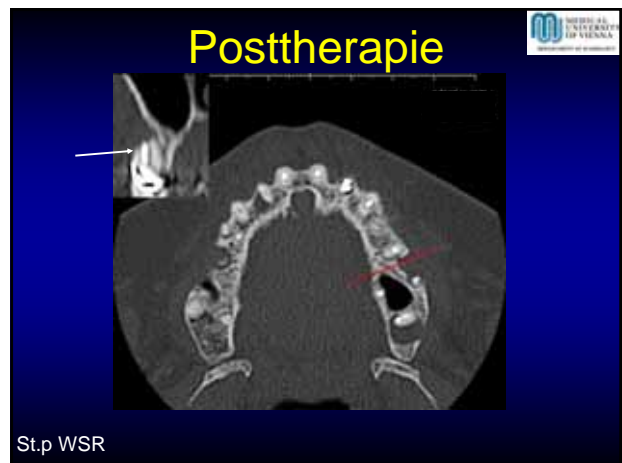
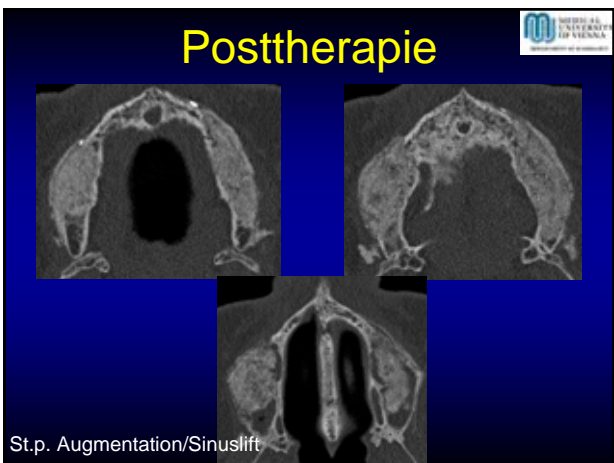
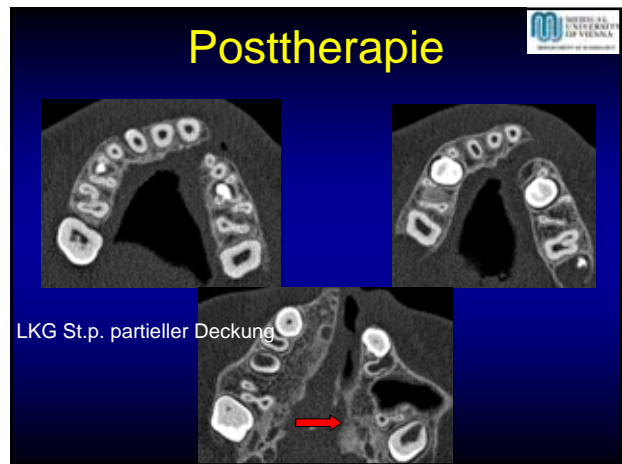
Trauma

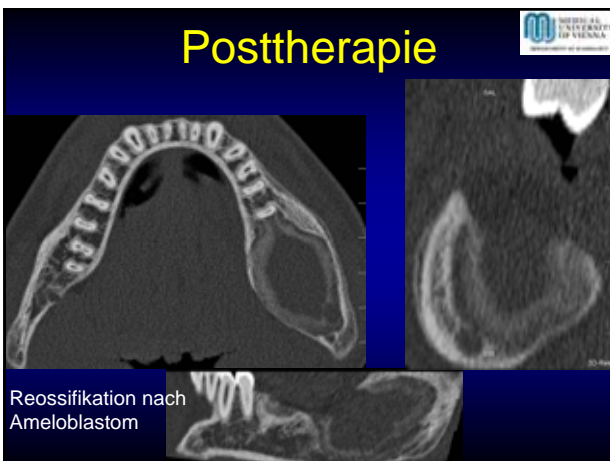
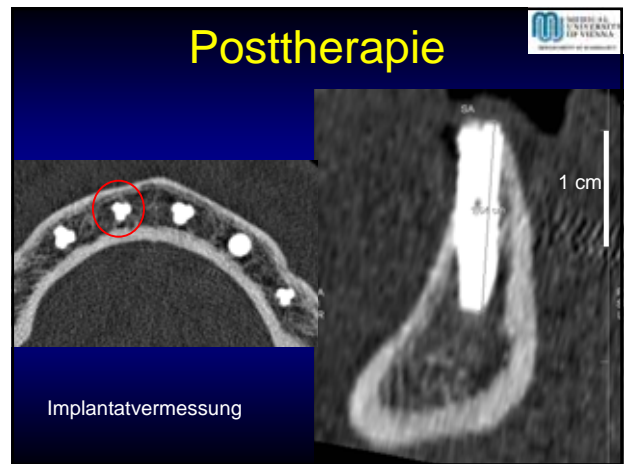
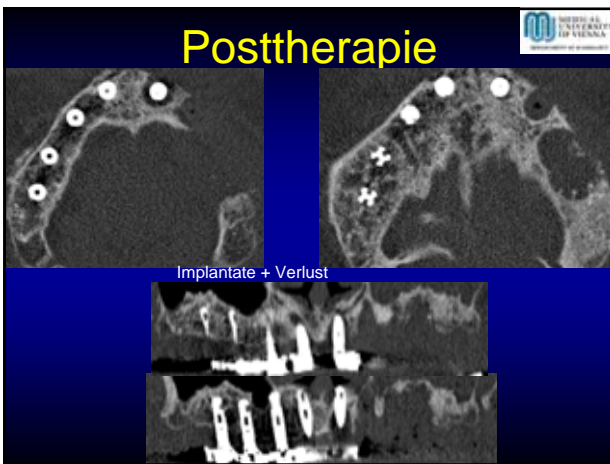
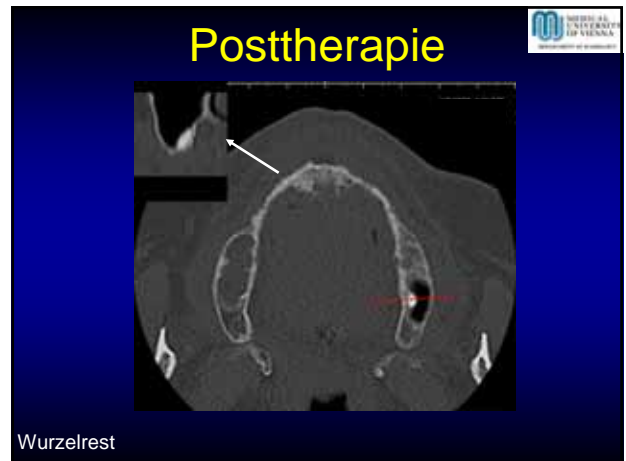
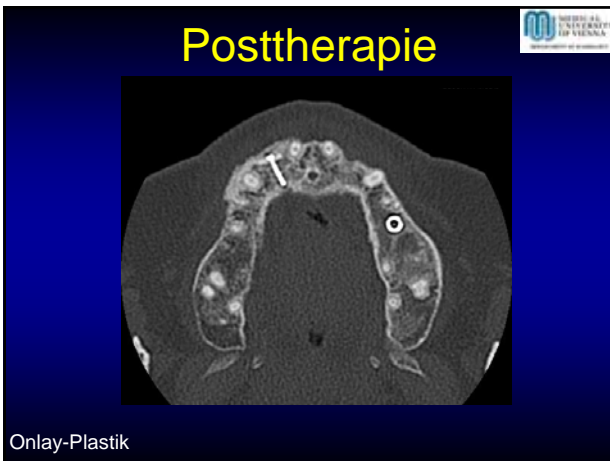
- Affektion von Zähnen/Wurzeln
- Affektion knöcherner Strukturen Ober-/Unterkiefer
- Kombination Zahn/Knochen





- ### Posttherapie
- Korrektur congenitaler Anomalien
 - Postentzündlich z.B. CAP reossifiziert
 - Postoperativ Tumor
 - Postoperativ Trauma





- ### Zusammenfassung
- MD-DentalCT exzellente Methode im Vgl. zu OPTG
 - Darstellung ohne Artefakte
 - Dentalrekonstruktionen jede Ebene + curved Rekonstruktionen ohne Stufen