

Case 1

63 year old male (R.K.)



Clinical findings / CVRF

Clinical findings

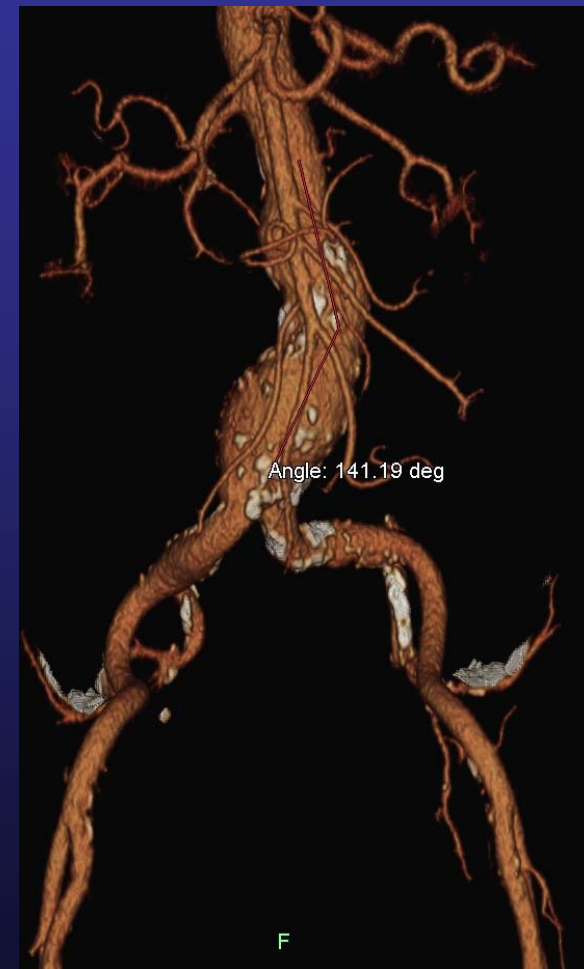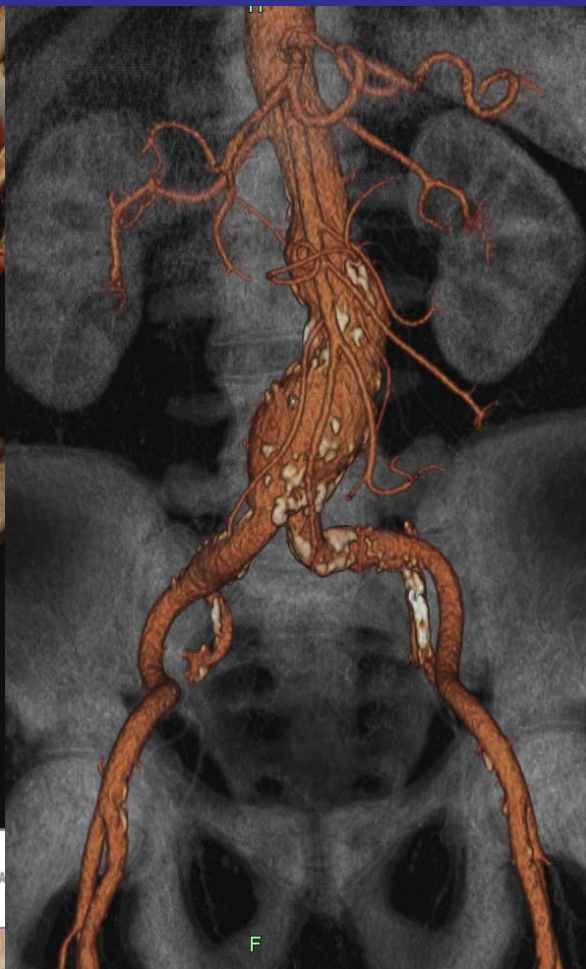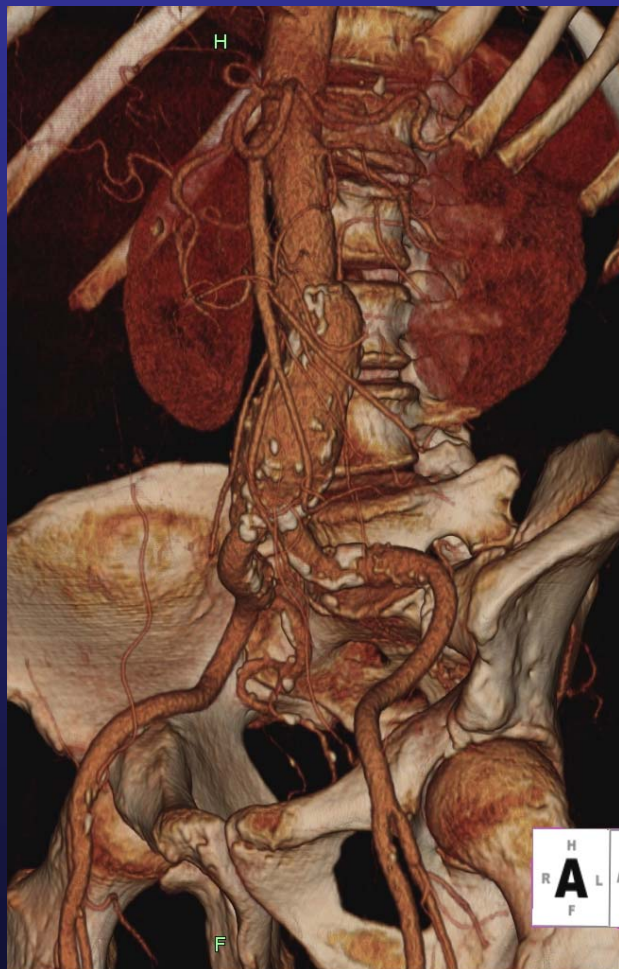
- Infrarenal AAA with increase in size during 1 year
- HIV, stable disease

Cardiovascular risk factors

- Mild hypertension
- Current smoker
- Hyperlipoproteinemia

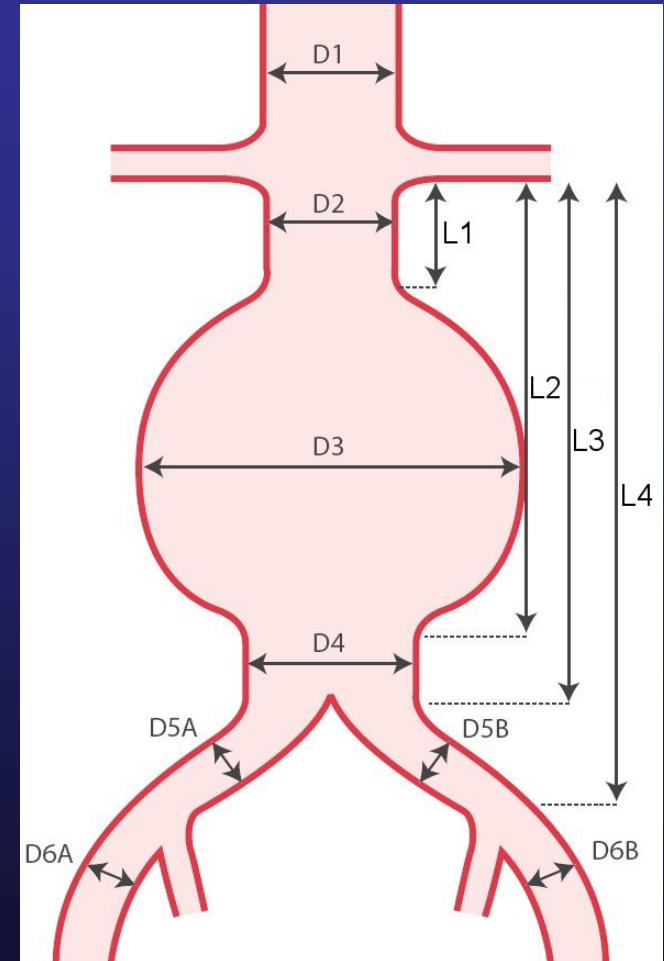


CTA findings



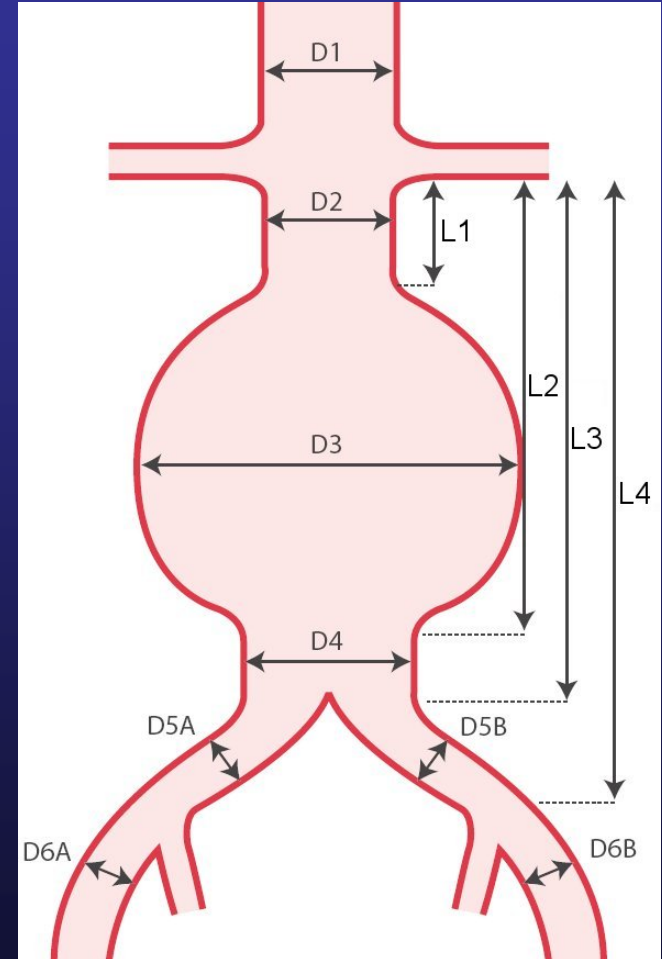
CTA findings – diameters

- Proximal LZ: 24mm
- Aortic neck: 27mm
- AAA diameter: 53mm
- Aortic Bifurcation: 24mm
- Distal LZ right: 16mm
- Distal LZ left: 16mm
- EIA diameter right: 11mm
- EIA diameter left: 9mm



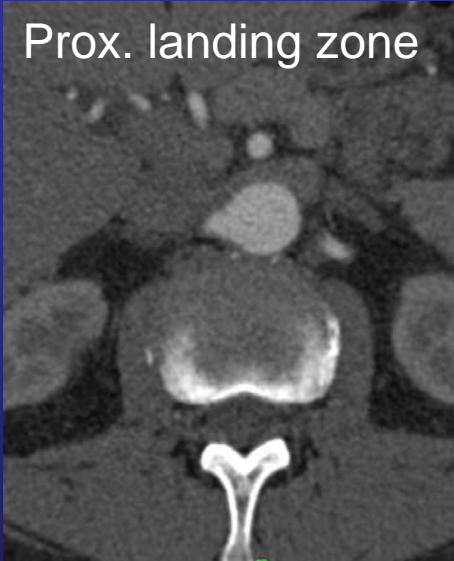
CTA findings – lengths

- Aortic neck (L1): 45mm
- AAA length (L2): 145mm
- Length L3: 145mm
- Length L4 right: 202mm
- Length L4 left: 197mm

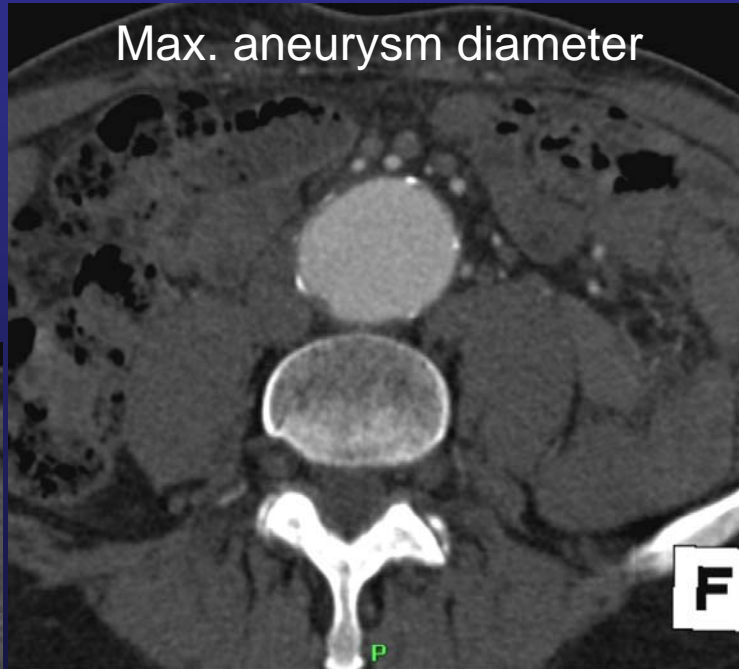


CTA findings

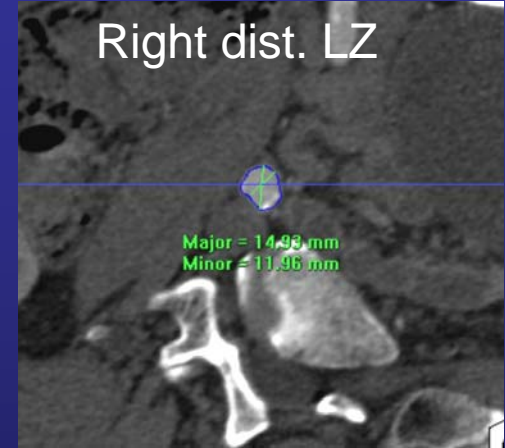Prox. landing zone



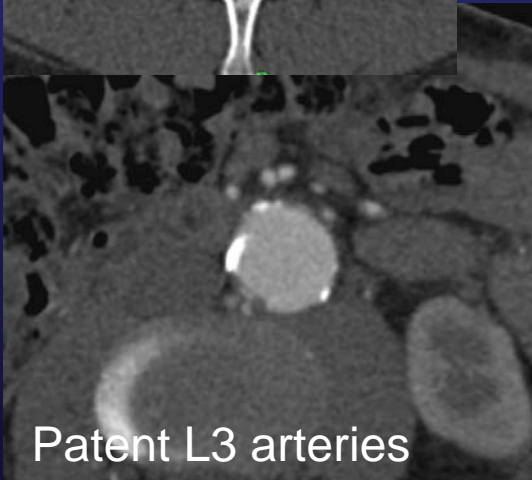
Max. aneurysm diameter



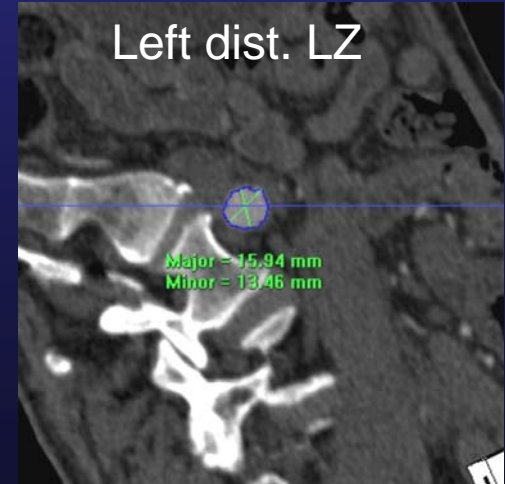Right dist. LZ



Patent L3 arteries



Left dist. LZ



Strategy

- Cut down in both groins
- Main body introduction via right femoral artery
- Guide wires / Catheters:
 - Terumo Glide guidewire 0.035“, 260cm
 - Cook Lunderquist guidewire 0.035“, 260cm
 - Boston 5F Pigtail catheter
 - Anaconda guiding catheter
- Stentgraft: Vascutek Anaconda
 - Size: Main body: 28/11.5 mm
Limbs: 16/140 mm
Extensions: 17/60 mm



Operateurs

- Jörn O. Balzer
- Thomas Schmitz-Rixen
- Piotr M. Kasprzak
- Thomas Lehnert



Case 2

76 year old female (E. K.-F.)



Clinical findings / CVRF

Clinical findings

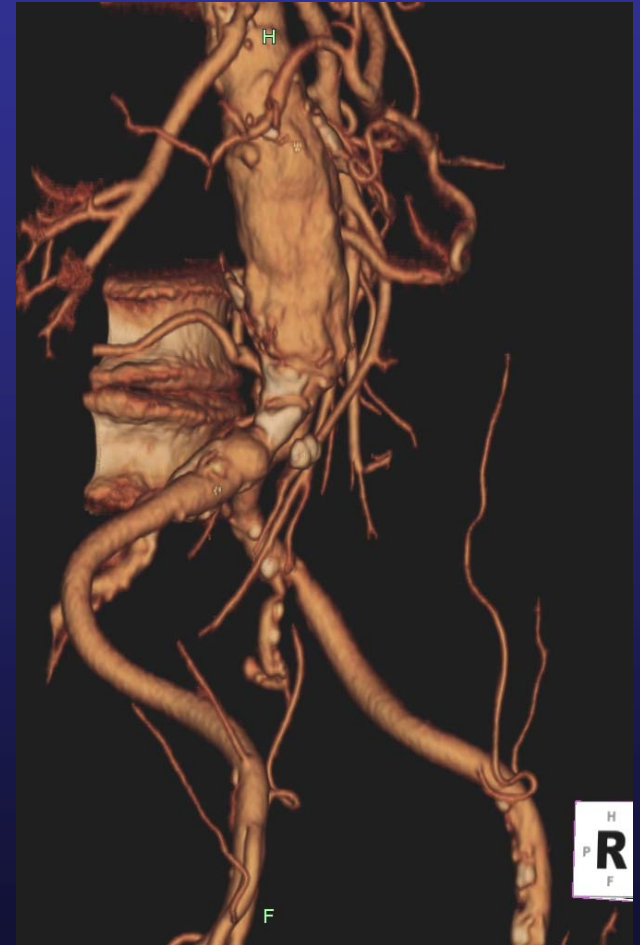
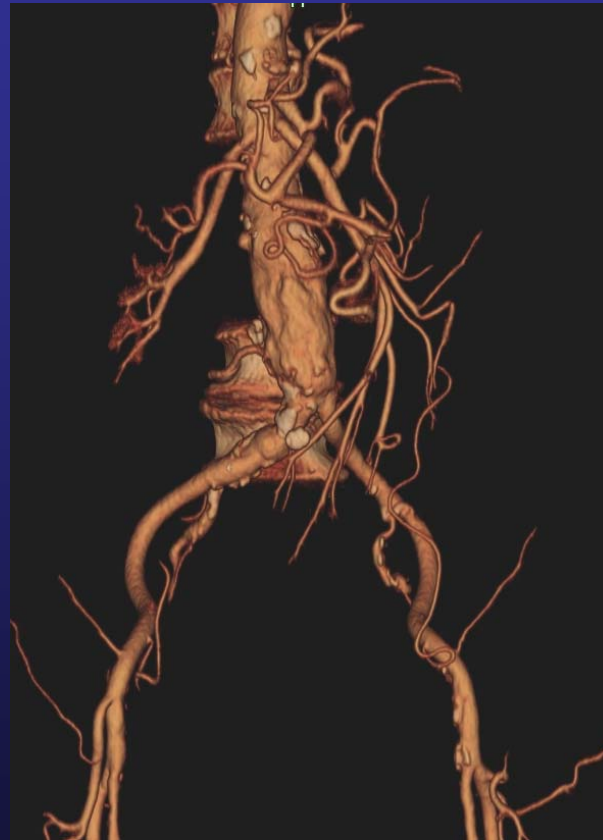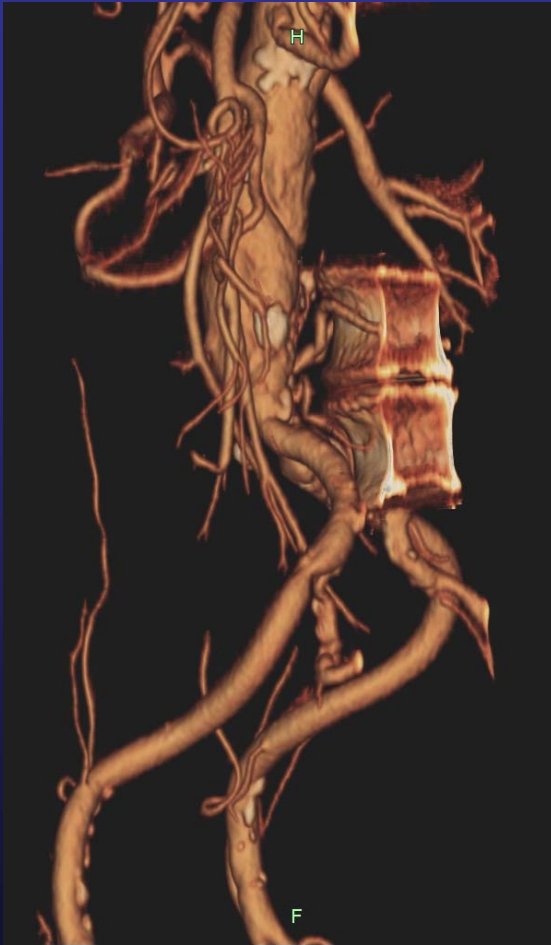- Infrarenal AAA

Cardiovascular risk factors

- Mild hypertension
- Current smoker
- Hyperlipoproteinemia

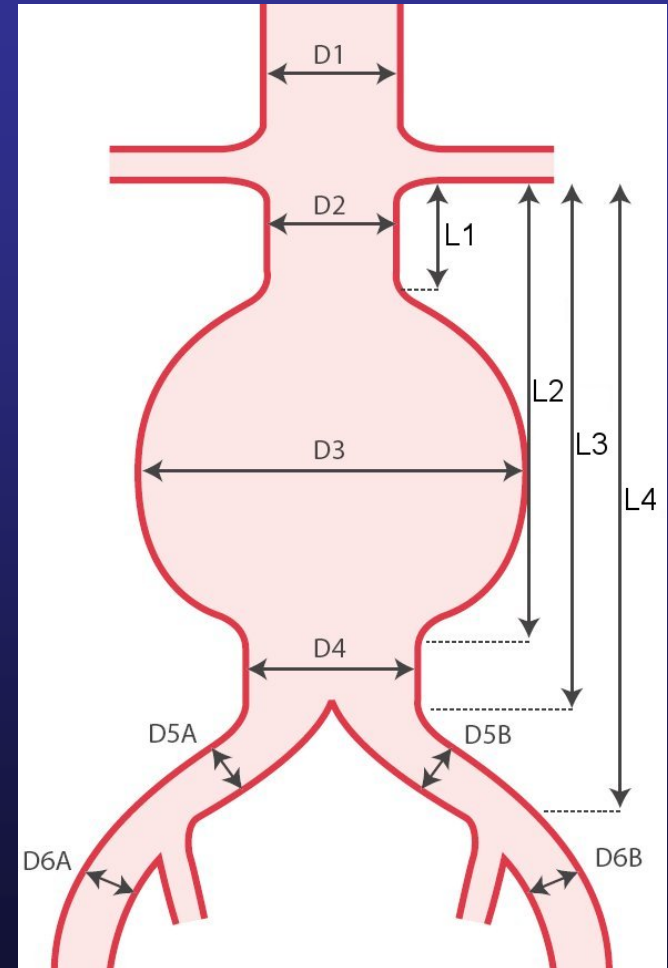


CTA findings



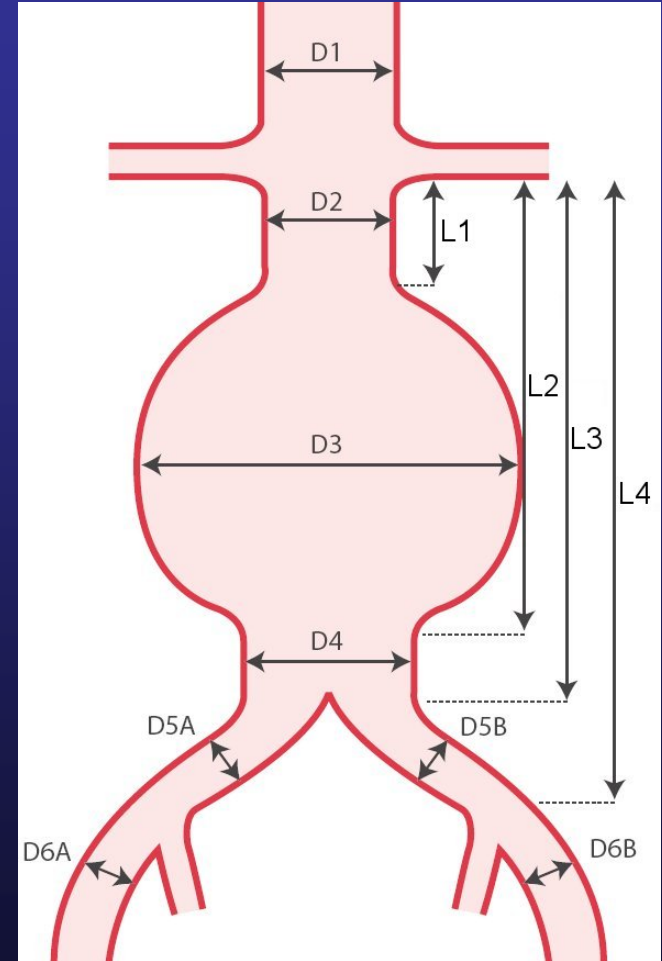
CTA findings – diameters

- Proximal LZ: 24mm
- Aortic neck: 28mm
- AAA diameter: 53mm
- Aortic Bifurcation: 19mm
- Distal LZ right: 14mm
- Distal LZ left: 11mm
- EIA diameter right: 9mm
- EIA diameter left: 8mm



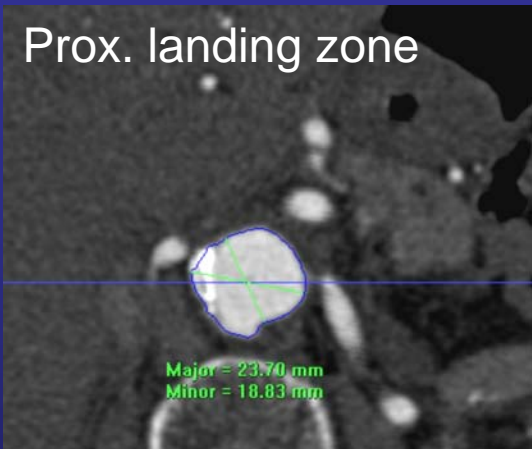
CTA findings – lengths

- Aortic neck (L1): 27mm
- AAA length (L2): 71mm
- Length L3: 98mm
- Length L4 right: 149mm
- Length L4 left: 168mm

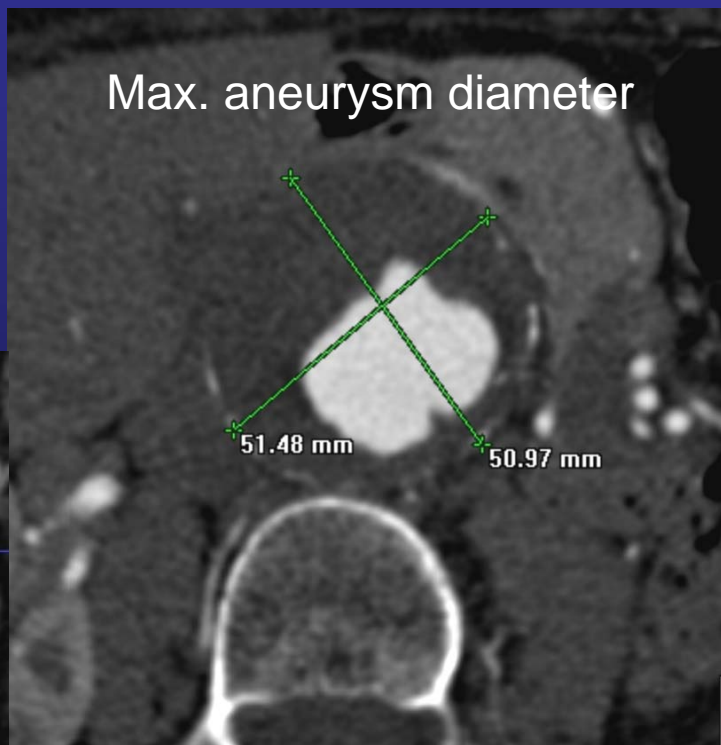


CTA findings

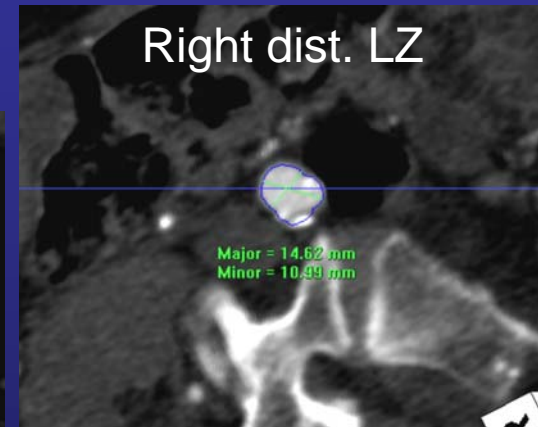
Prox. landing zone



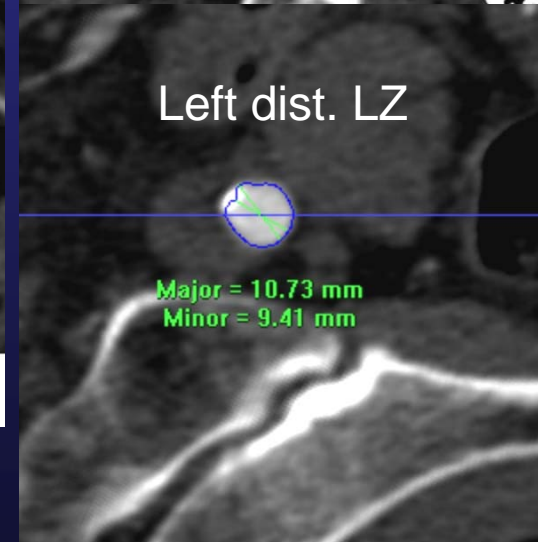Max. aneurysm diameter



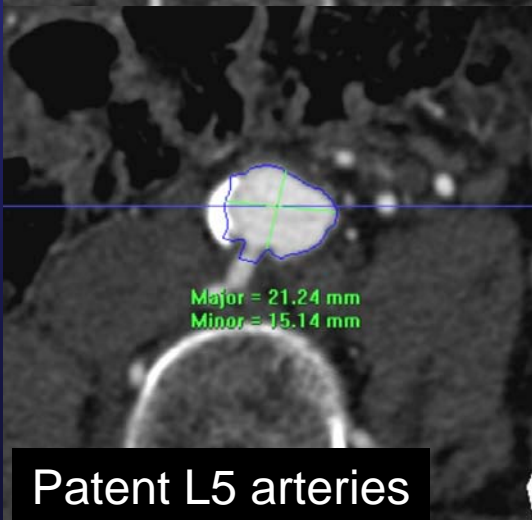
Right dist. LZ



Left dist. LZ



Patent L5 arteries



Strategy

- Coil embolization of L5 arteries
- Cut down in both groins
- Main body introduction via right femoral artery
- Guide wires / Catheters:
 - Terumo Glide guidewire 0.035“, 260cm
 - Cook Lunderquist guidewire 0.035“, 260cm
 - Boston 5F Pigtail Catheter
 - Cordis 5F Multipurpose catheter
- Stentgraft: Talent
 - Size:



Operateurs

- Axel Thalhammer
- Farzin Adili
- Thomas Schmandra
- Stefan Zangos



Case 3

83 year old male (K.-H. B.)



Clinical findings / CVRF

Clinical findings

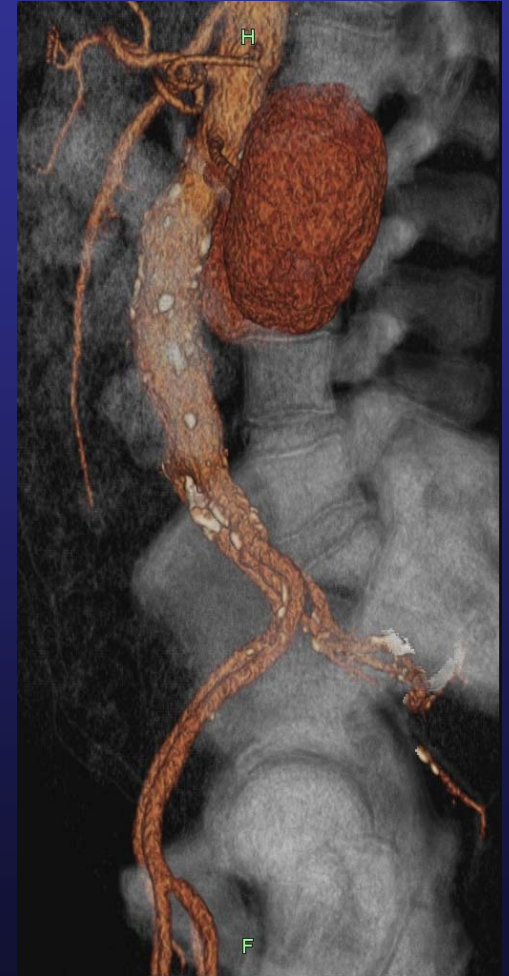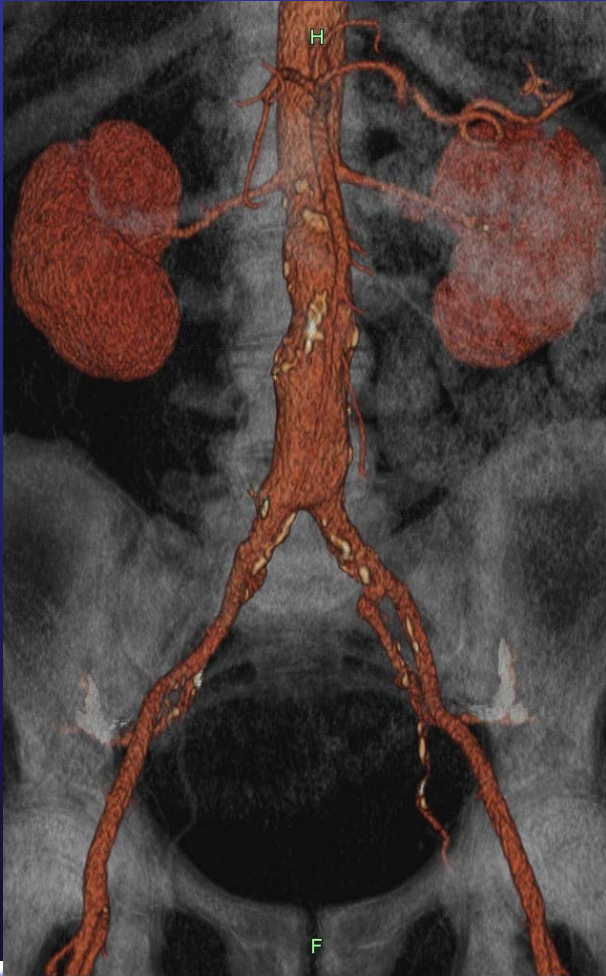
- Infrarenal AAA with increase in size during 1 year
- CHD with MI, COPD

Cardiovascular risk factors

- Hypertension
- Current smoker
- Hyperlipoproteinemia

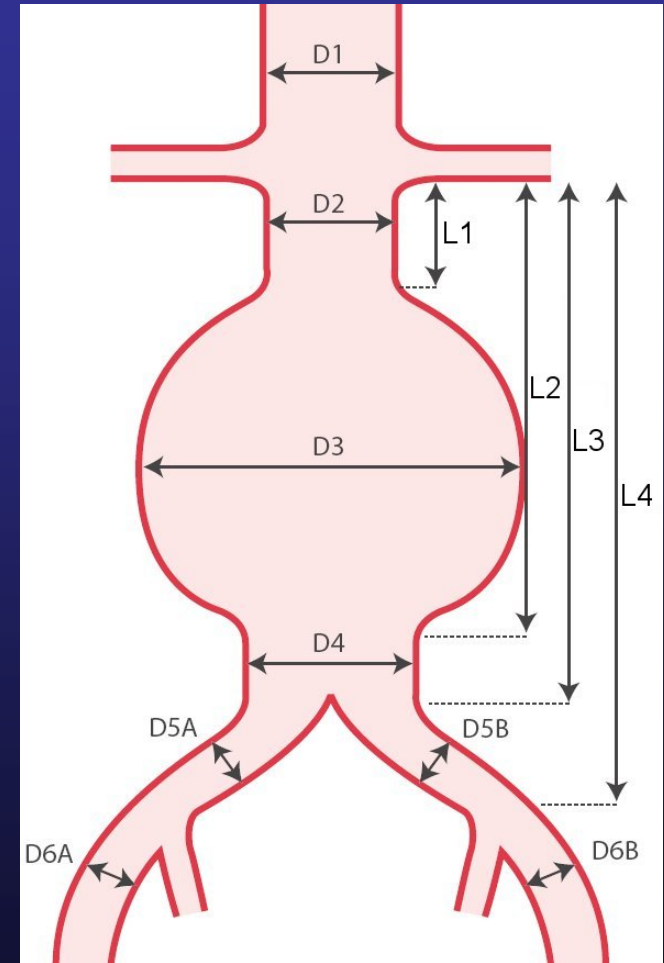


CTA findings



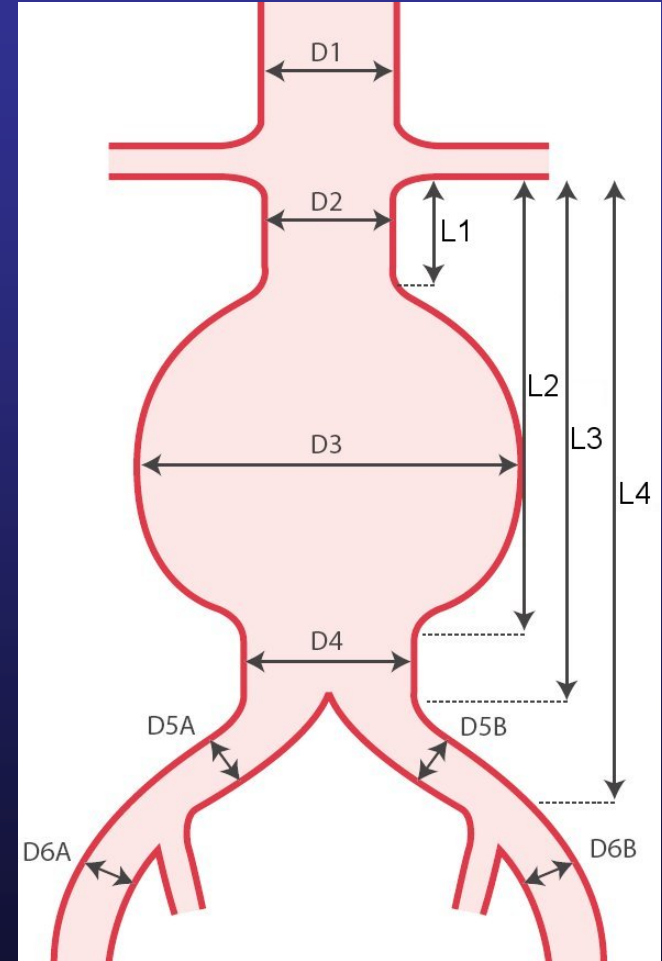
CTA findings – diameters

- Proximal LZ: 22mm
- Aortic neck: 22mm
- AAA diameter: 53mm
- Aortic Bifurcation: 24mm
- Distal LZ right: 13mm
- Distal LZ left: 14mm
- EIA diameter right: 9mm
- EIA diameter left: 9mm

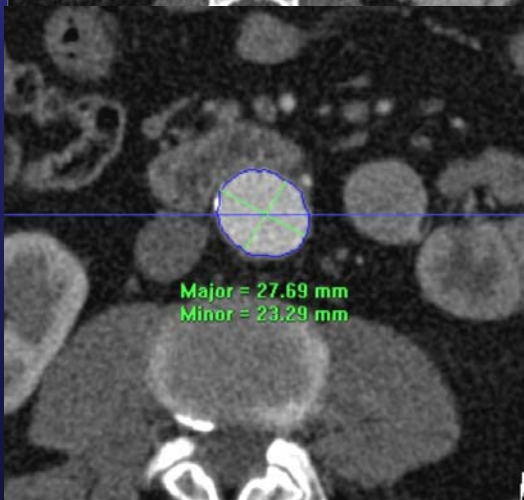
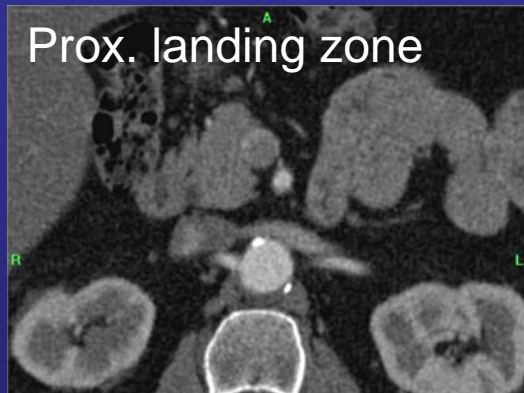

CTA findings – lengths

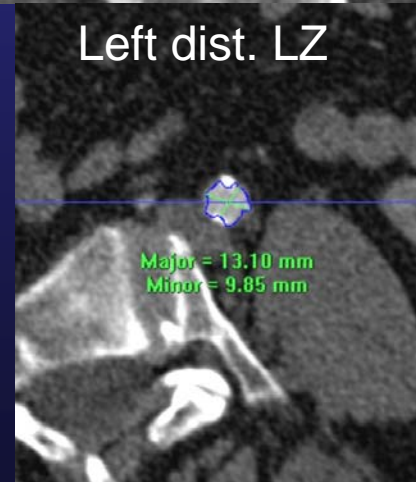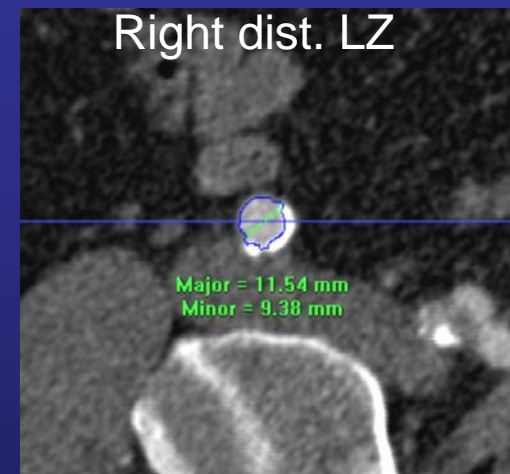
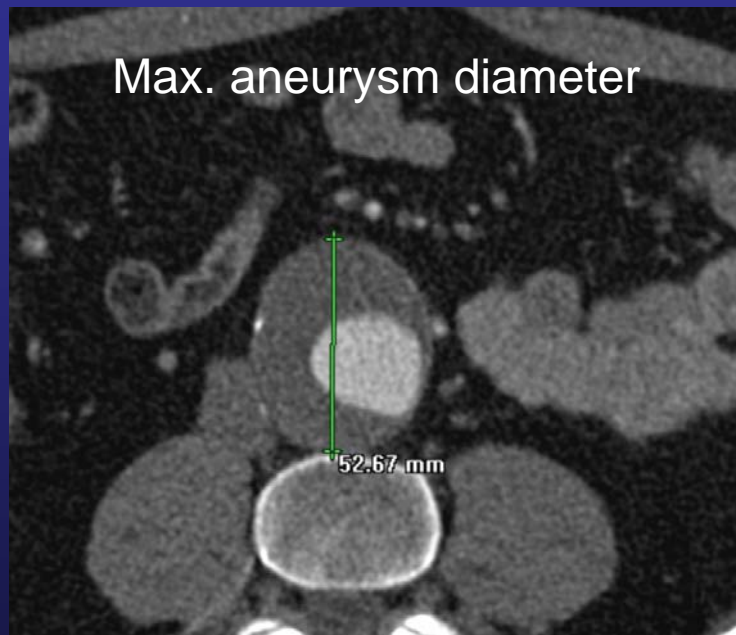
- Aortic neck (L1): 18 mm
- AAA length (L2): 90 mm
- Length L3: 90 mm
- Length L4 right: 148 mm
- Length L4 left: 156 mm



CTA findings



Diameter in aortic neck



Strategy

- Cut down in both groins
- Main body introduction via left femoral artery
- Guide wires / Catheters:
 - Terumo Glide guidewire 0.035", 260cm
 - Cook Lunderquist 0.035", 260cm
 - Boston 5F Pigtail catheter
 - Cordis 5F Multipurpose catheter or 5F SOS Omnis catheter
- Stentgraft: Cook
 - Size: Main body: 26/96 mm
Limbs: 14/37 mm (ipsil.), 14/54 (contral.)



Operateurs

- Jörn O. Balzer
- Thomas Schmitz-Rixen
- Mathias Tenholt
- Thomas Lehnert

